

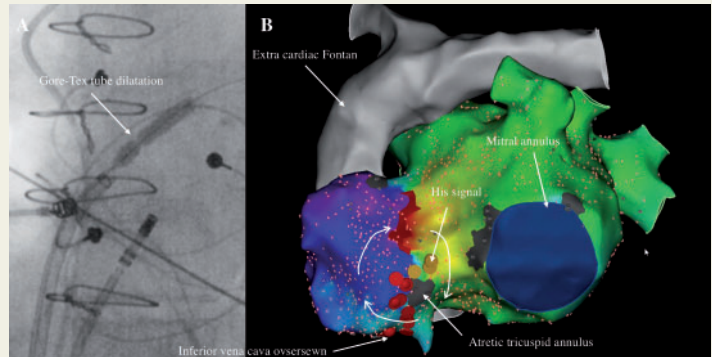
## Intra-atrial re-entrant tachycardia around atretic tricuspid annulus

Victor Waldmann<sup>1,2,3,4\*</sup>, Denis Amet<sup>1</sup>, Magalie Ladouceur<sup>2,3,4</sup>, Gilles Soulat<sup>2,3,4,5</sup>, Eloi Marijon<sup>1,3,4</sup>, and Laurence Iserin<sup>2,3</sup>

<sup>1</sup>Electrophysiology Unit, Department of Cardiology, European Georges Pompidou Hospital, Paris, France; <sup>2</sup>Adult Congenital Heart Disease Unit, Department of Cardiology, European Georges Pompidou Hospital, Paris, France; <sup>3</sup>University of Paris, Paris, France; <sup>4</sup>Paris Cardiovascular Research Center, INSERM U970, Paris, France; and <sup>5</sup>Department of Radiology, European Georges Pompidou Hospital, Paris, France

\* Corresponding author. Tel: +33 676098007; fax: +33 156095466. E-mail address: victor.waldmann@inserm.fr

A 47-year-old woman with tricuspid atresia and extra-cardiac Fontan palliation who developed symptomatic atrial arrhythmia was referred for catheter ablation. The clinical arrhythmia was easily inducible with a stable tachycardia cycle length of 260 ms. Trans-Gore-Tex tube puncture was performed, and multiple dilatations up to a 6-mm cutting balloon were required to allow the introduction of a steerable sheath (Agilis NxT™, Abbott) (Panel A). Bi-atrial activation and entrainment mapping using a high-density mapping catheter (Pentaray, Biosense) revealed a macro intra-atrial re-entrant tachycardia around the atretic tricuspid annulus identified by a small scar area near to the His signal (Panel B, propagation map video is



provided in [Supplementary material online](#)). We performed a linear ablation between the atretic tricuspid annulus and the scar where the inferior vena cava was oversewn. The arrhythmia slowed then terminated during the second radiofrequency application. The conduction block was confirmed by activation mapping, and no further atrial arrhythmia was inducible. In patients with extra-cardiac conduits, the isthmus between the atrioventricular valve annulus and the oversewn inferior vena cava is often involved. In this case, despite the absence of tricuspid valve due to tricuspid atresia, the arrhythmia circuit rotated around the atretic annulus identified by a small scar area.

[Supplementary material](#) is available at *Europace* online.

The full-length version of this report can be viewed at: <https://www.escardio.org/Education/E-Learning/Clinical-cases/Electrophysiology>.

Published on behalf of the European Society of Cardiology. All rights reserved. © The Author(s) 2019. For permissions, please email: [journals.permissions@oup.com](mailto:journals.permissions@oup.com).