IRM et Scanner cardiaques: Indications en pédiatrie

Francesca Raimondi
Hôpital Necker-Enfant Malades, Paris

Indications partagées

- **Anatomie**

  Intracardiaque:

  - *Etude pre et post-operatoire*
  - *Tumeurs, thrombus, péricarde*

  Extracardiaque

  - Gros vaisseaux
  - Shunts et montages chirurgicaux
  - Artères coronaires proximales

Scanner vs IRM

- **Scanner**
  - ✓ *Irradiant*
  - ✓ *Examen court*
  - ✓ *Haute disponibilité*
- **IRM**
  - ✓ *Non irradiant*
  - ✓ *Examen long*
  - ✓ *Disponibilité limitée*

Indications Scanner

Anatomie

- Analyse des artères coronaires
- Détails anatomiques dans les pathologies de gros vaisseaux et rapport avec les bronches
- Etude des collatérales aorto-pulmonaires
- Etude du parenchyme pulmonaire

Indications Scanner

Analyse des artères coronaires

- ✓ Confirmer une anomalie coronaire vue à l'echo (ALCAPA, ARCAPA..)
- ✓ Contrôle post opératoire (anomalie coronaire, TGV)

SnapShot Pulse: How it works



Prospective ECG gating Axial and Step & Shoot

Real-time heart rate monitoring and gating

Not a *single* phase; it is a phase *range*

Dose and exposure time are heart rate independent

Prospectively gated acquisition – SnapShot Pulse

X-ray on time

Target Phase range

Retrospective gating helical acquisition

imagination at work

SnapShot Pulse: How it works

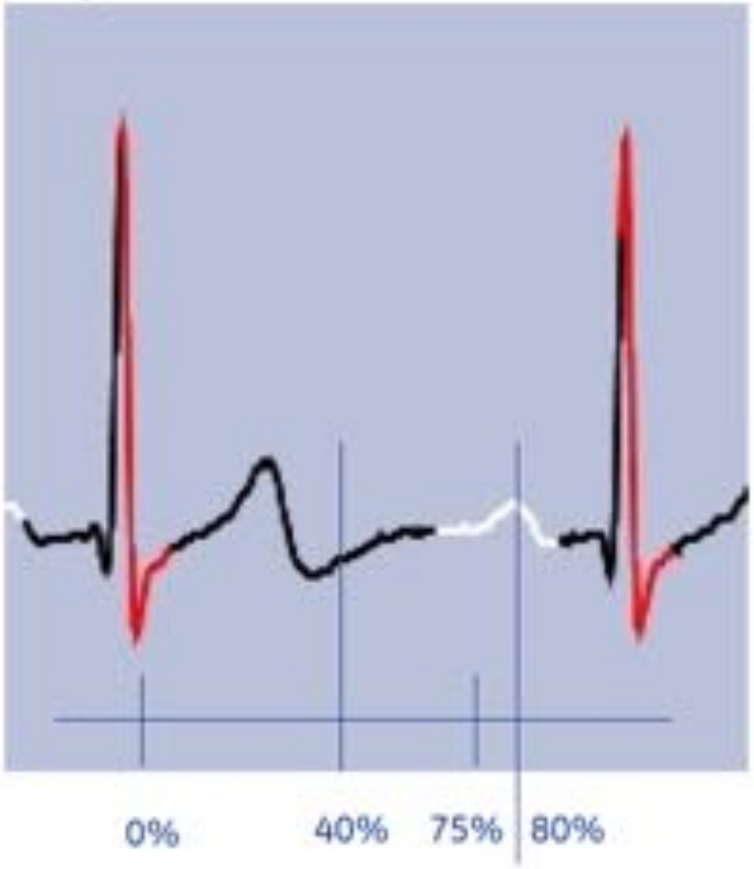

Best phases for coronary study

- If HR<65 bpm: best phase for RCA and LCA is 70%-80%
- If HR> 65 bpm: 80% for LCA

  40% for RCA

When HR is low, only diastolic phase is need for coronary artery assessment

If HR is high, systolic phase is needed whatever the temporal resolution, this is physiological

Helical versus Pulse

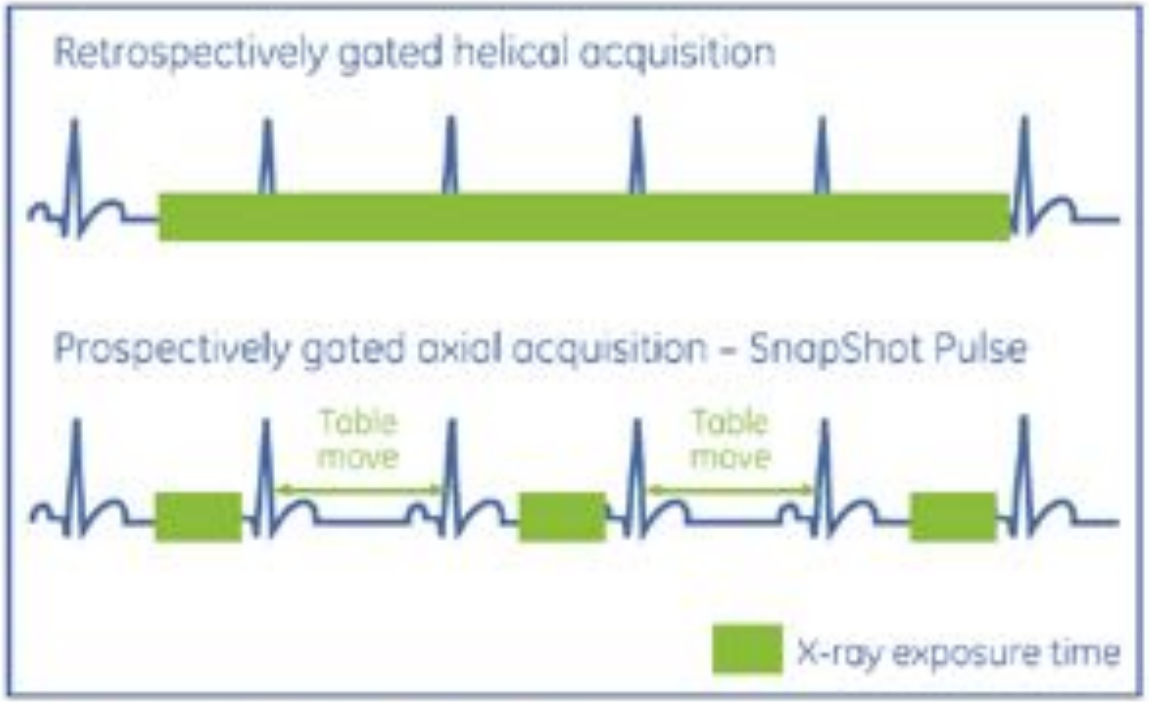

Helical with ECG mod

SnapShot Pulse

Helical: pitch 0.16-0.24 →overbeaming

S.Pulse: Axial: pitch 1→ No overbeaming

Scanner coronaire à Necker

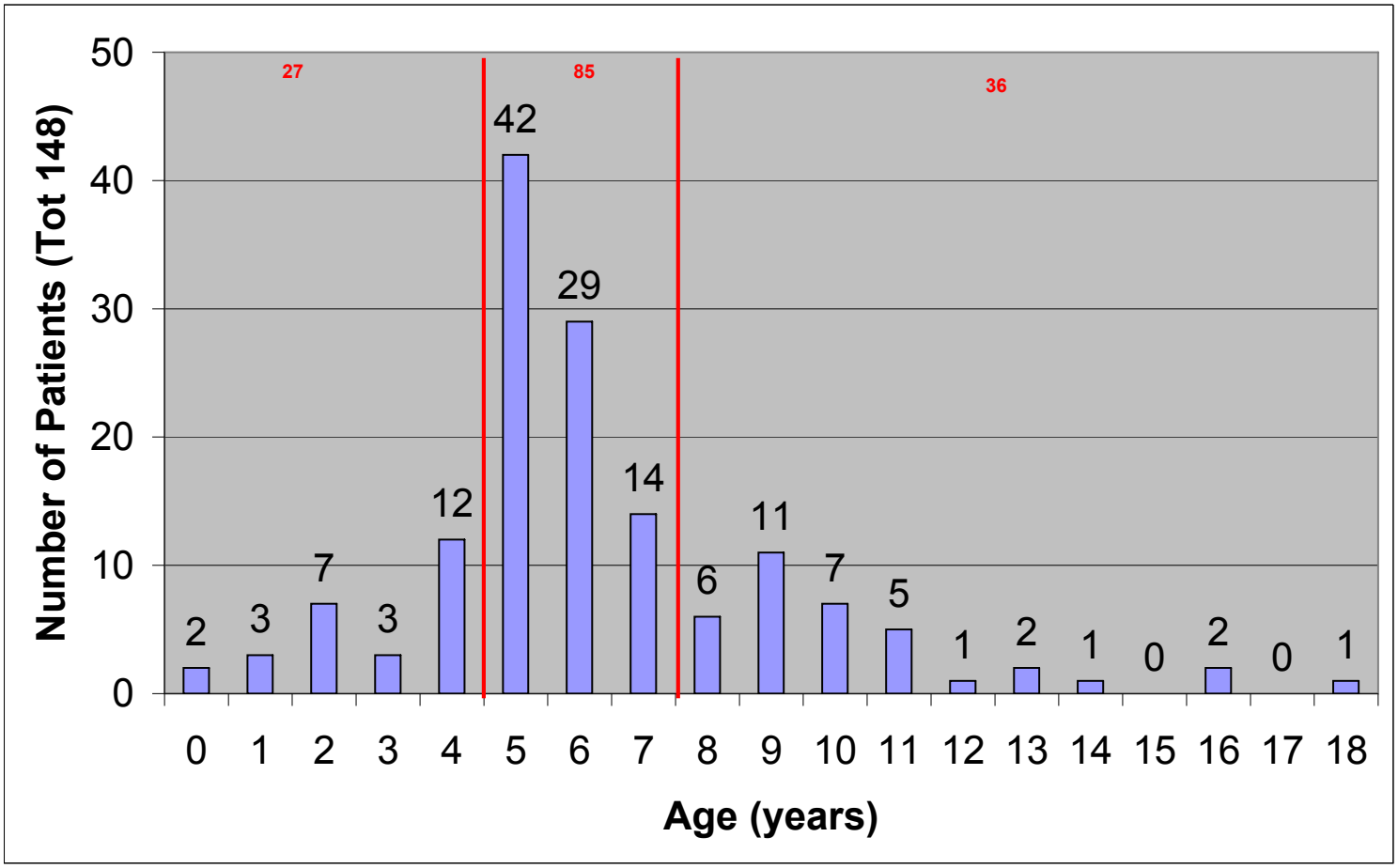

Scanner coronaire à Necker

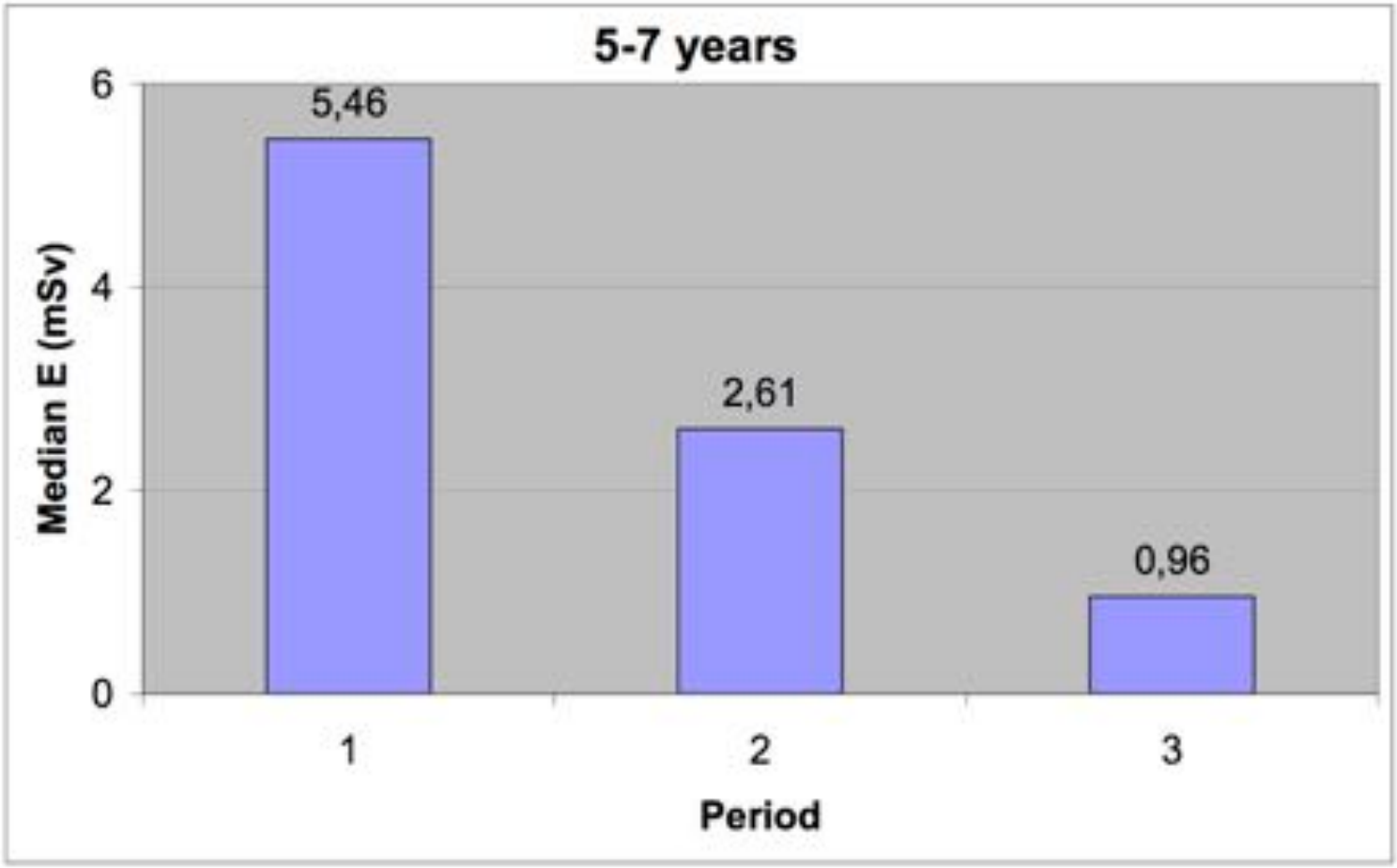

Scanner coronaire à Necker

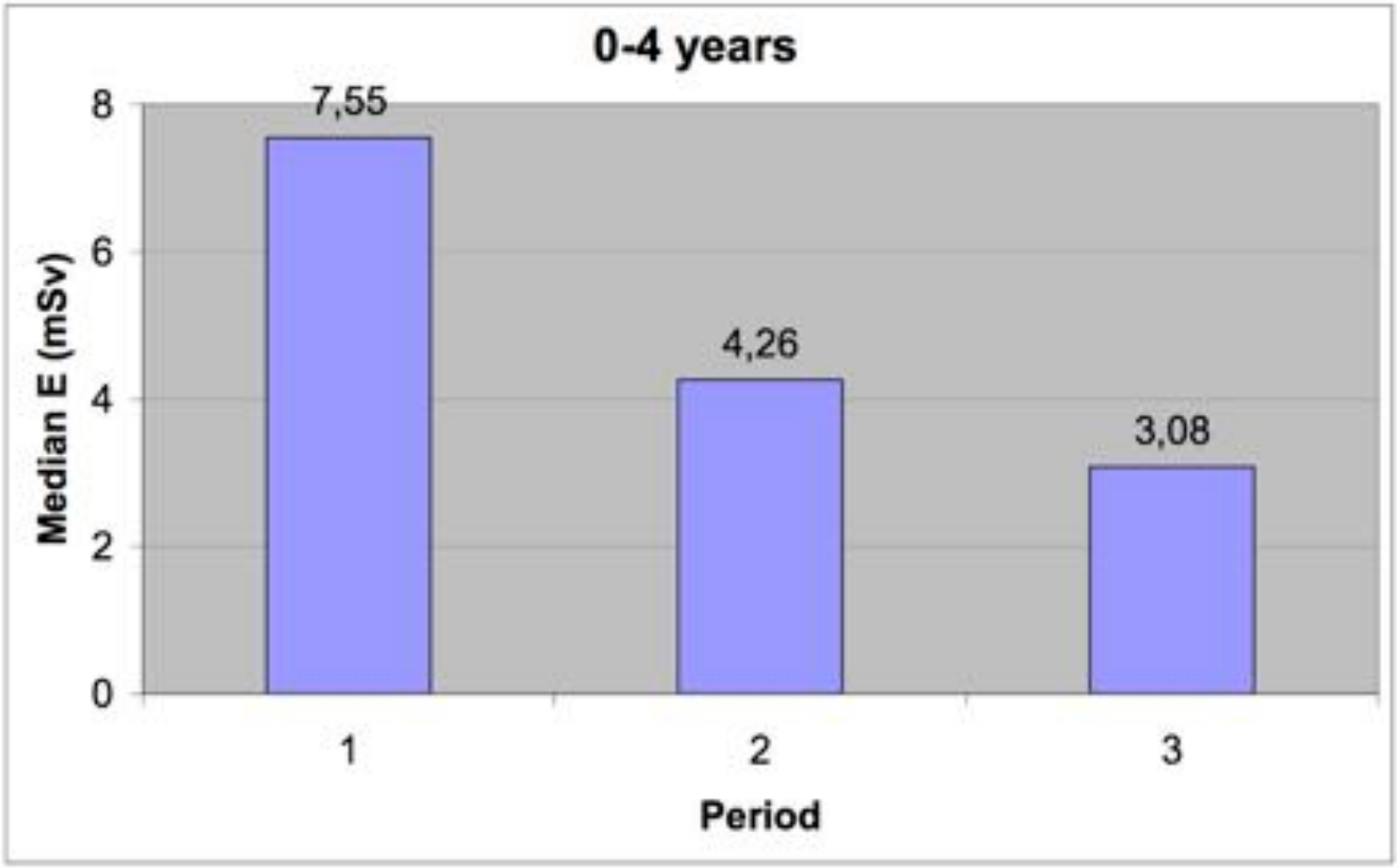

Scanner coronaire à Necker

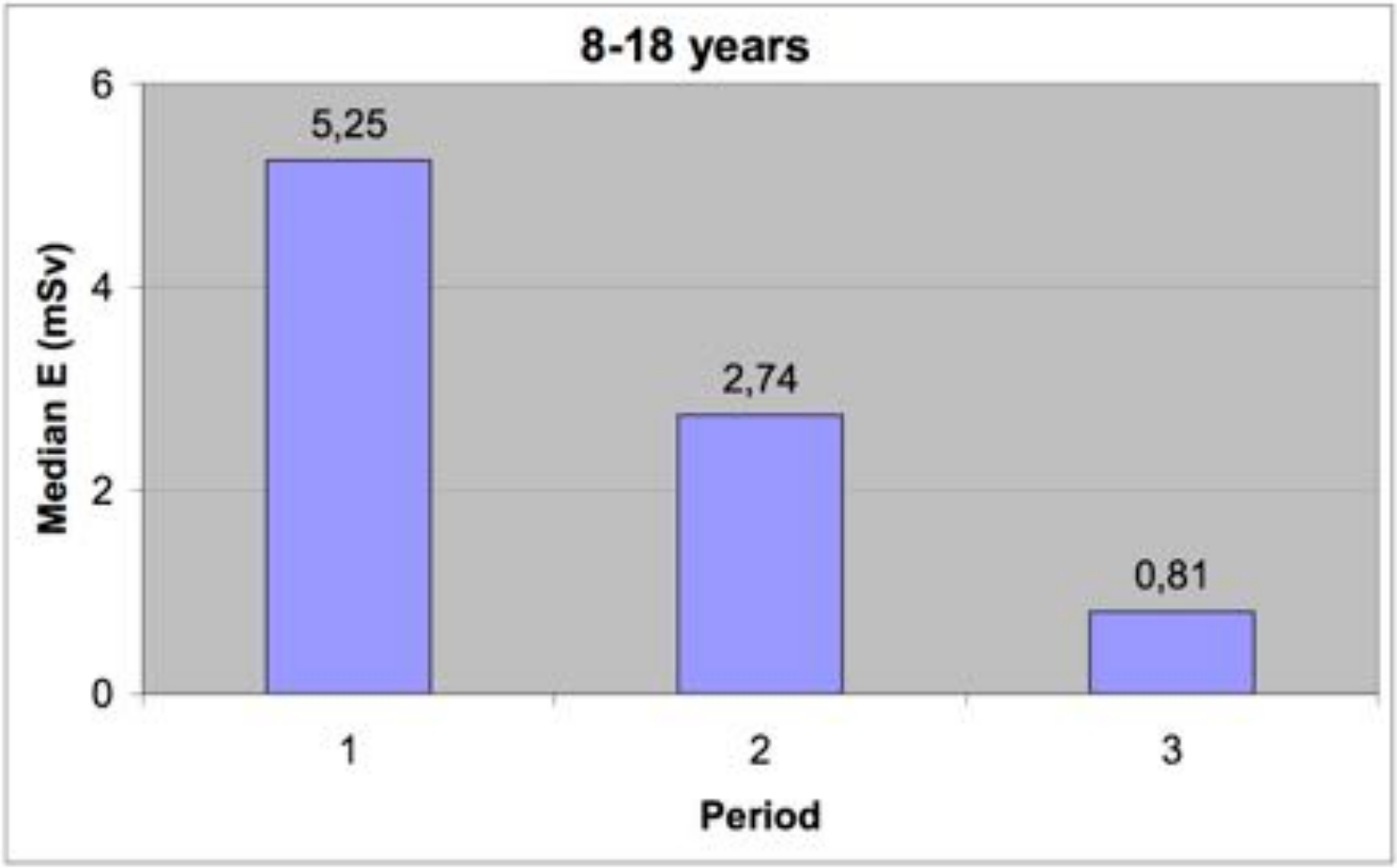

Scanner - Gating prospectif

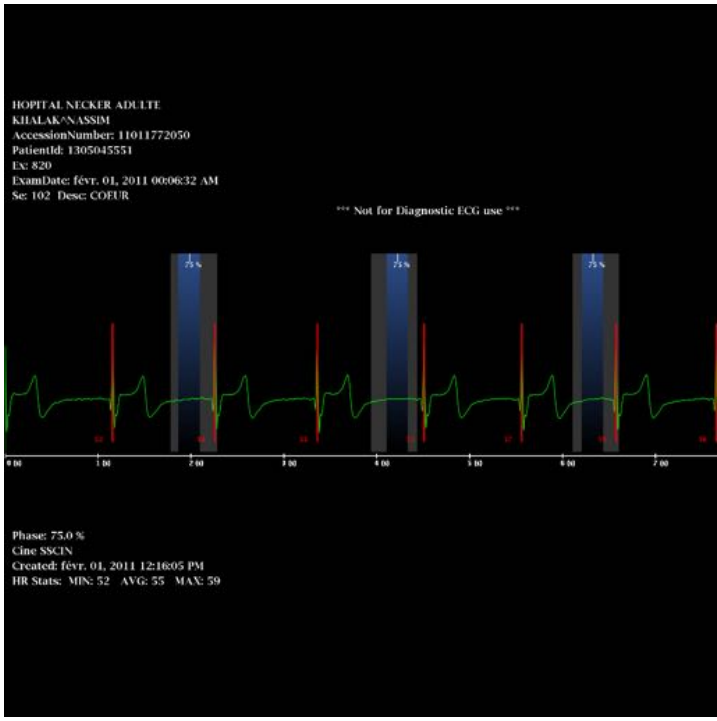

0,952 mSv

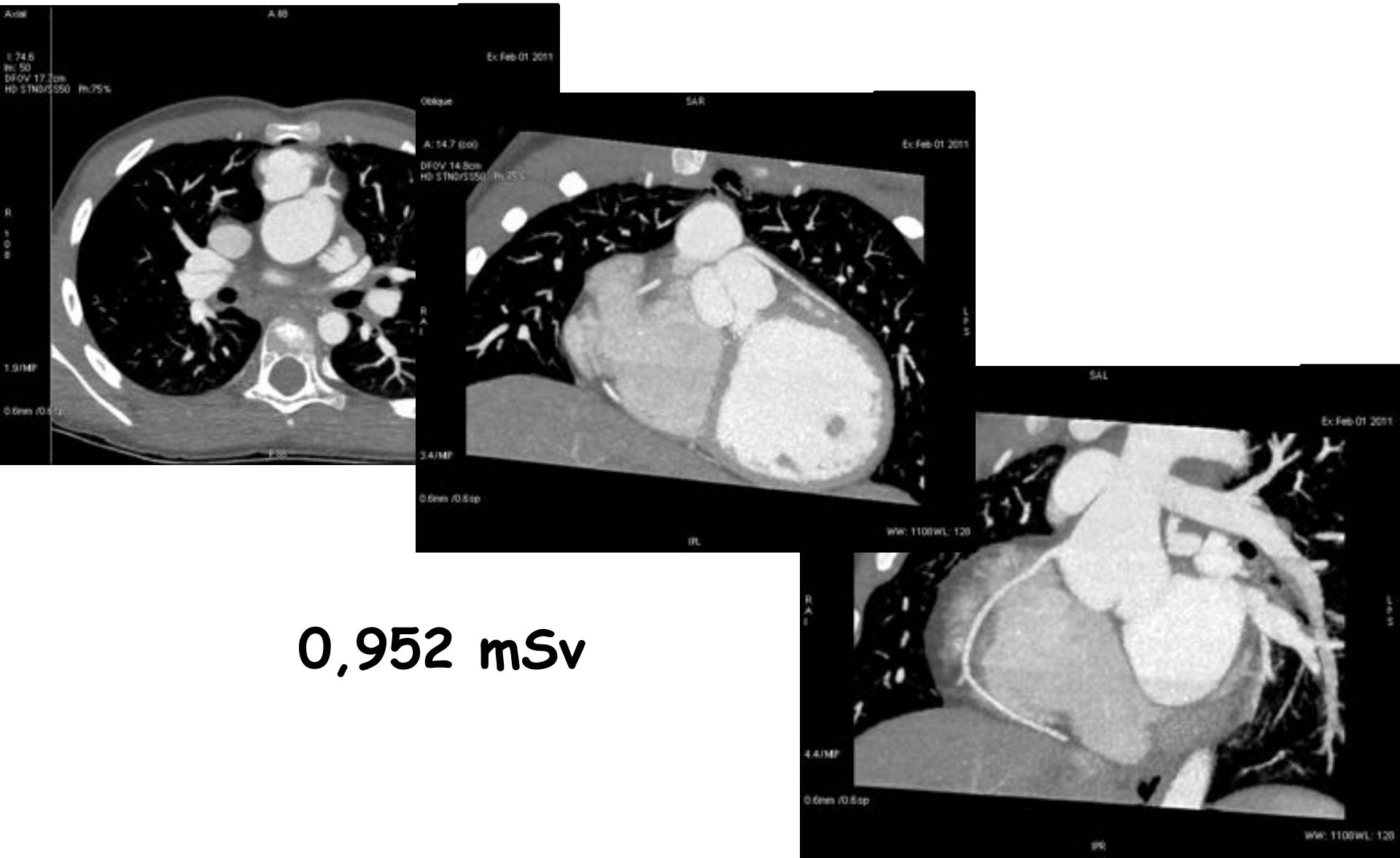
Axial
A 88
Ex:Feb 01 2011
Oblique
SAR
A: 14.7 (col)
DFOV 14.8cm
Ex:Feb 01 2011
3.4/MP
0.6mm /0.6sp
IRL
WW: 1100WL: 120
SAL
Ex:Feb 01 2011
4.4/MP
0.6mm /0.6sp
IPR
WW: 1100WL: 120

0,952 mSv

CDx
S
I

CDx

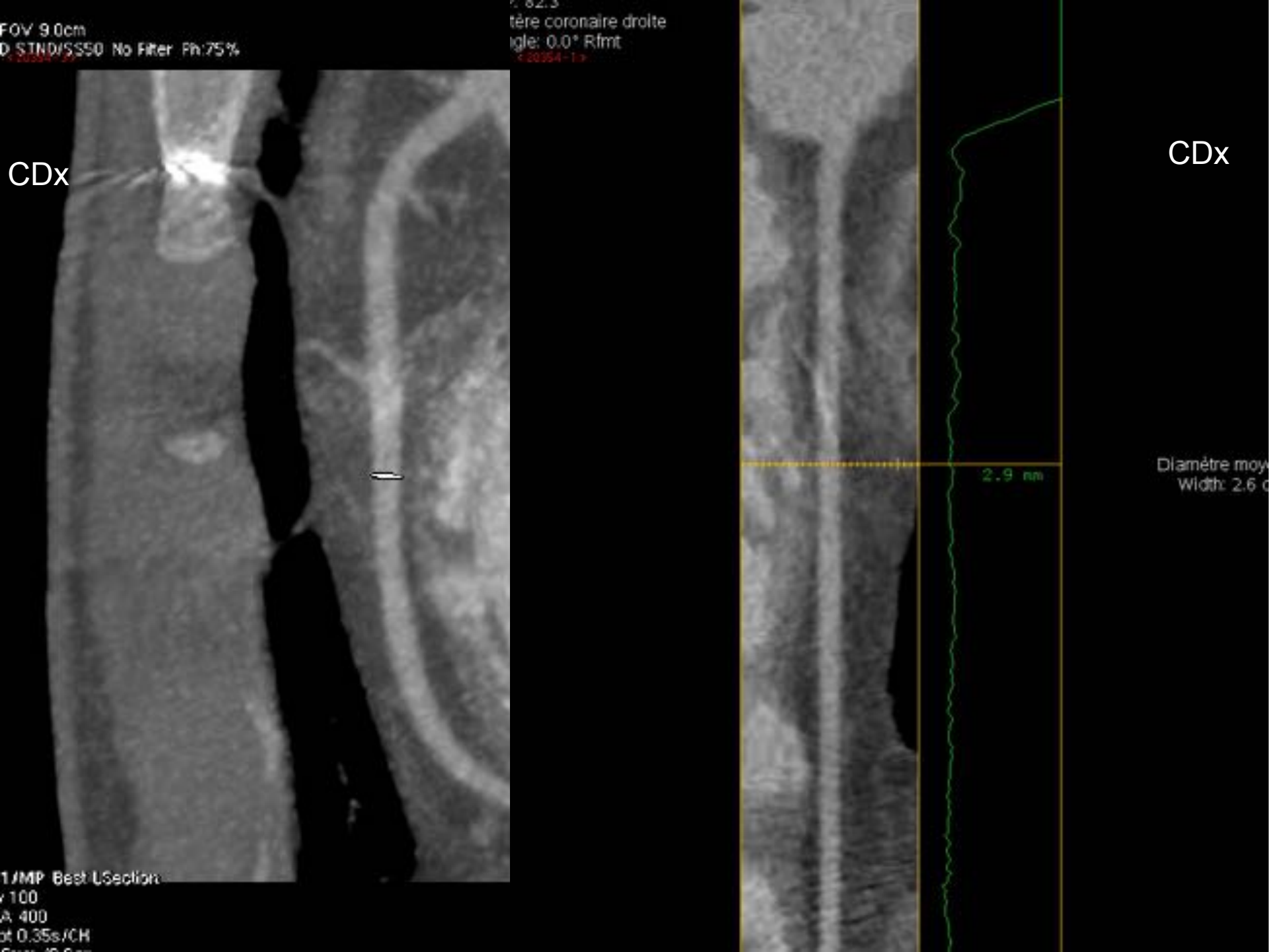
FOV 9.0cm
D STND/SS50 No Filter Fh:75%
tère coronaire droite
gle: 0.0° Rfmt
CDx
1/MP Best LSection
100
A 400
t 0.35s/CH
2.9 mm
CDx
Diamètre moy
Width: 2.6

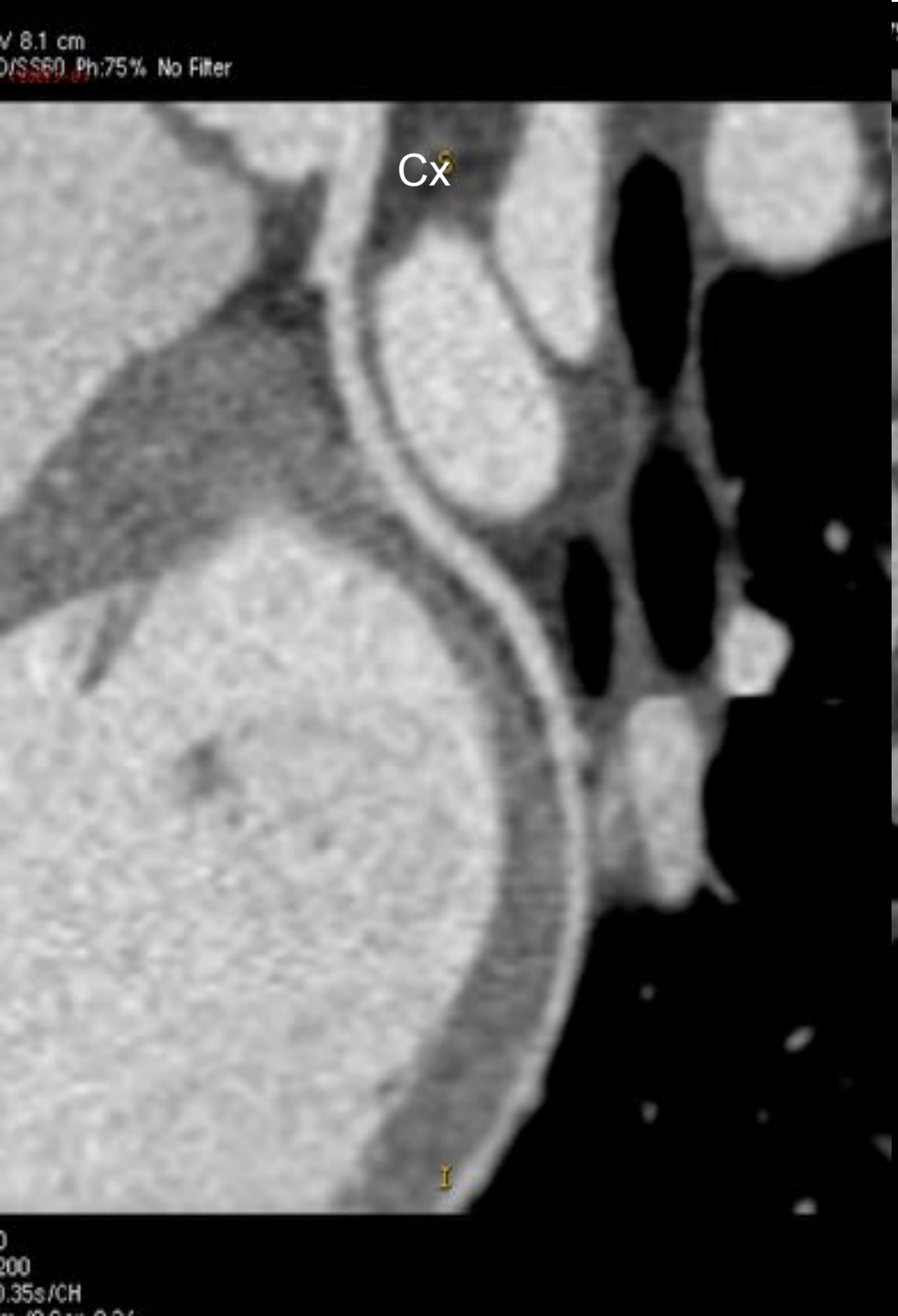
V 8.1 cm
D/SS60 Ph:75% No Filter
Cx
I
200
0.35s/CH

5% No Filter
A
Cx
P

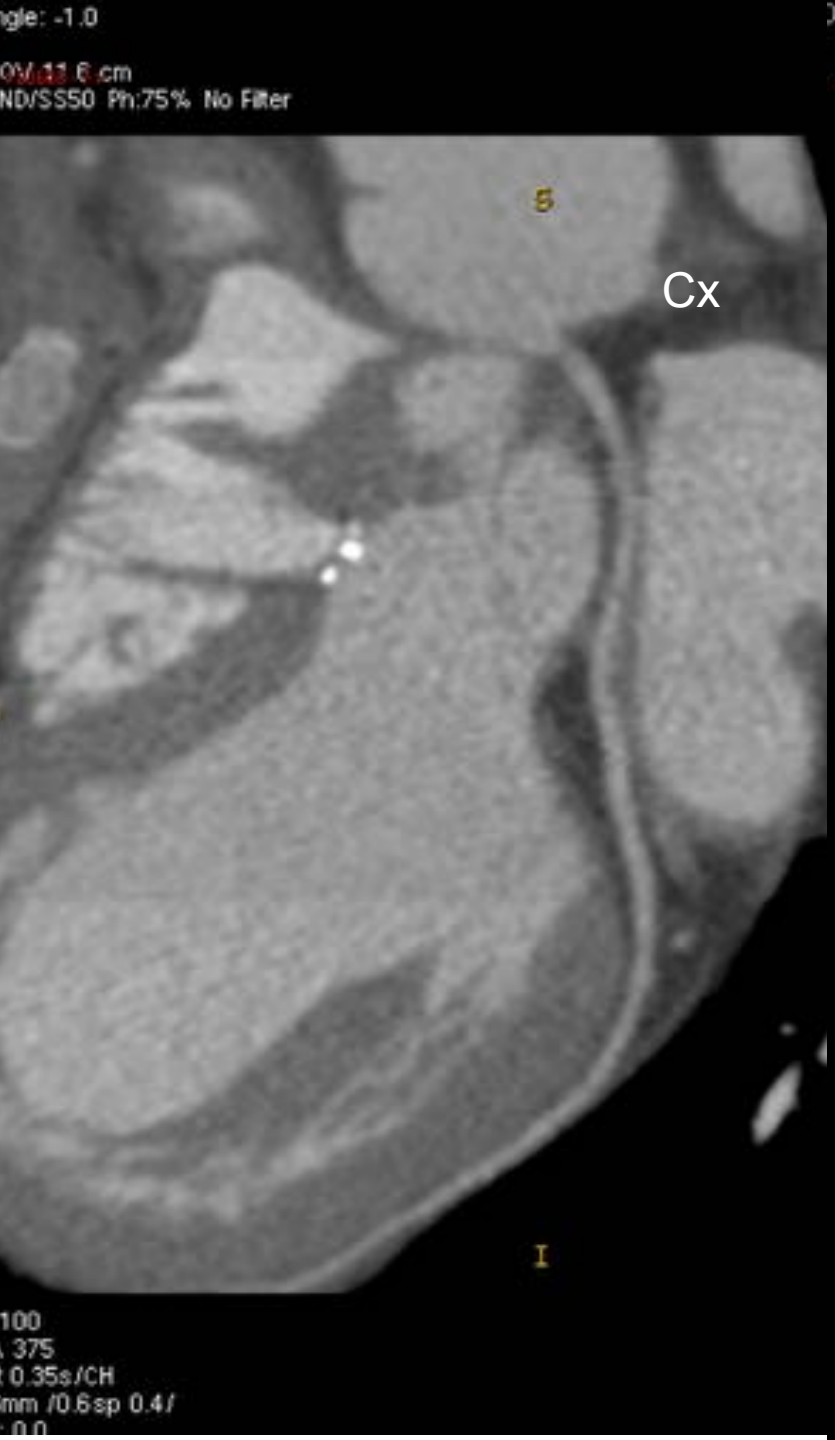
gle: -1.0
cm
ND/SS50 Ph:75% No Filter
S
Cx
I
100
375
0.35s/CH
mm /0.6sp 0.4/

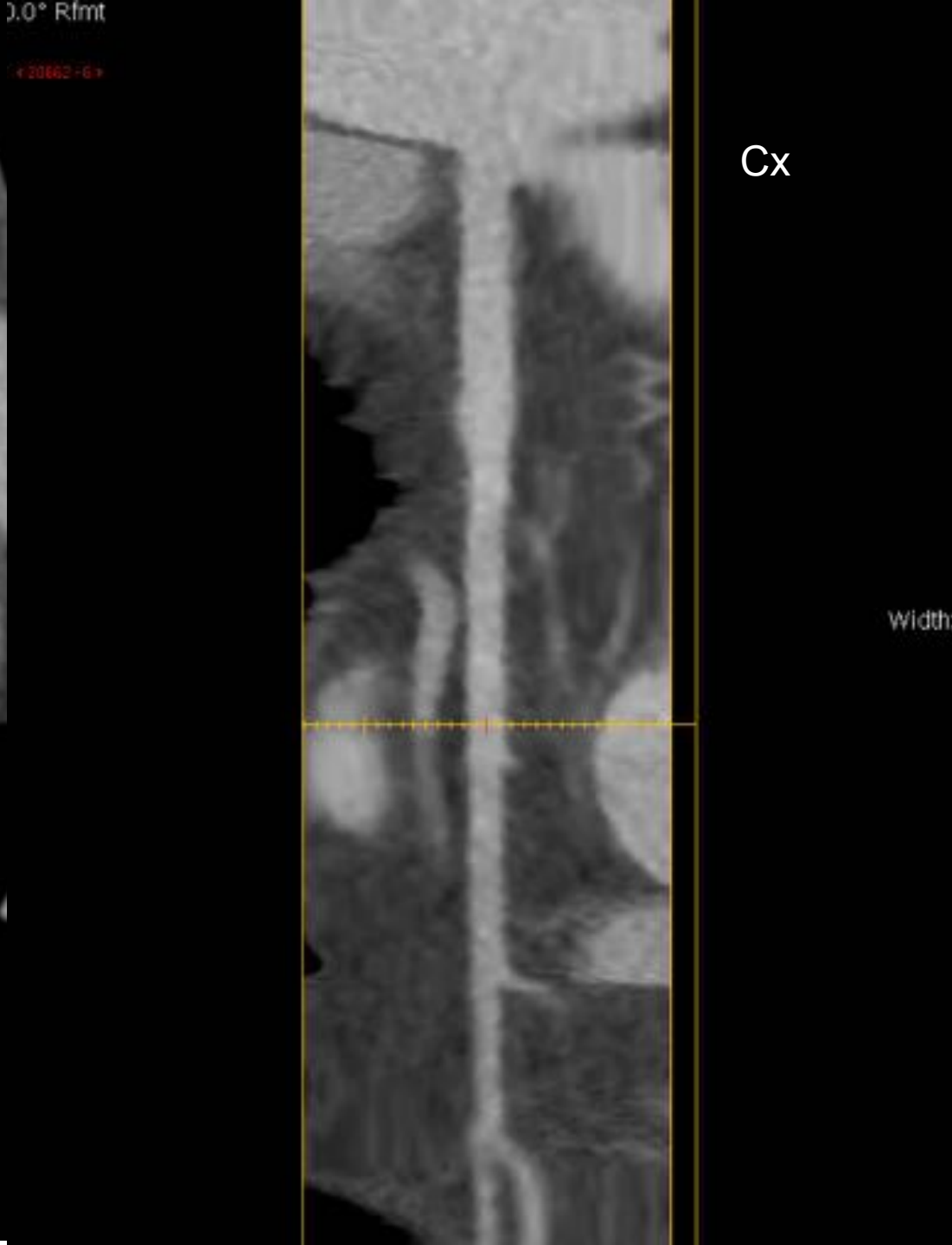
0.0° Rfmt
Cx
Width

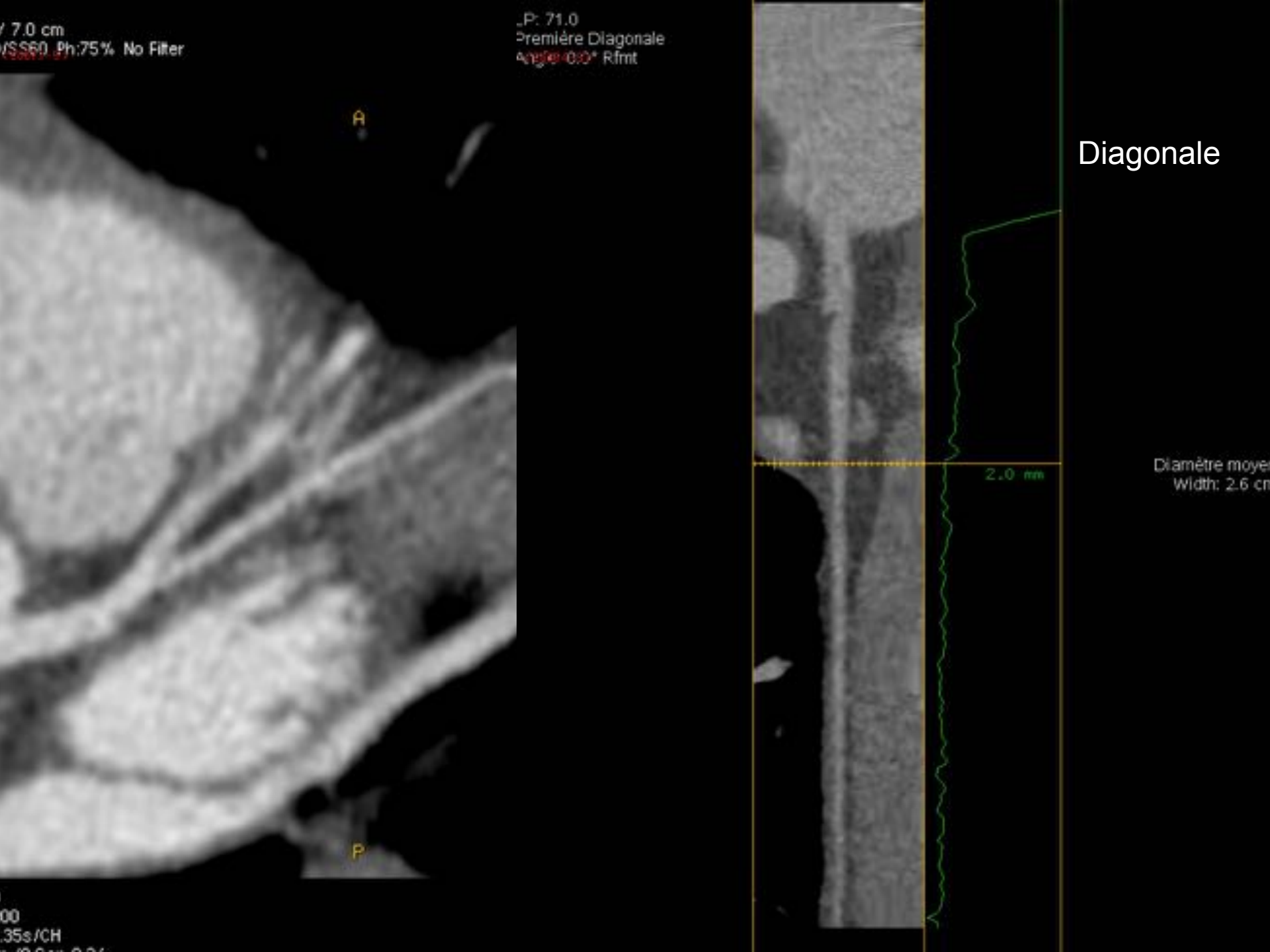
/ 7.0 cm
/SS60 Ph:75% No Filter
LP: 71.0
Première Diagonale
Rfmt
A
P
2.0 mm
Diamètre moye
Width: 2.6 cm
00
.35s/CH

Diagonale

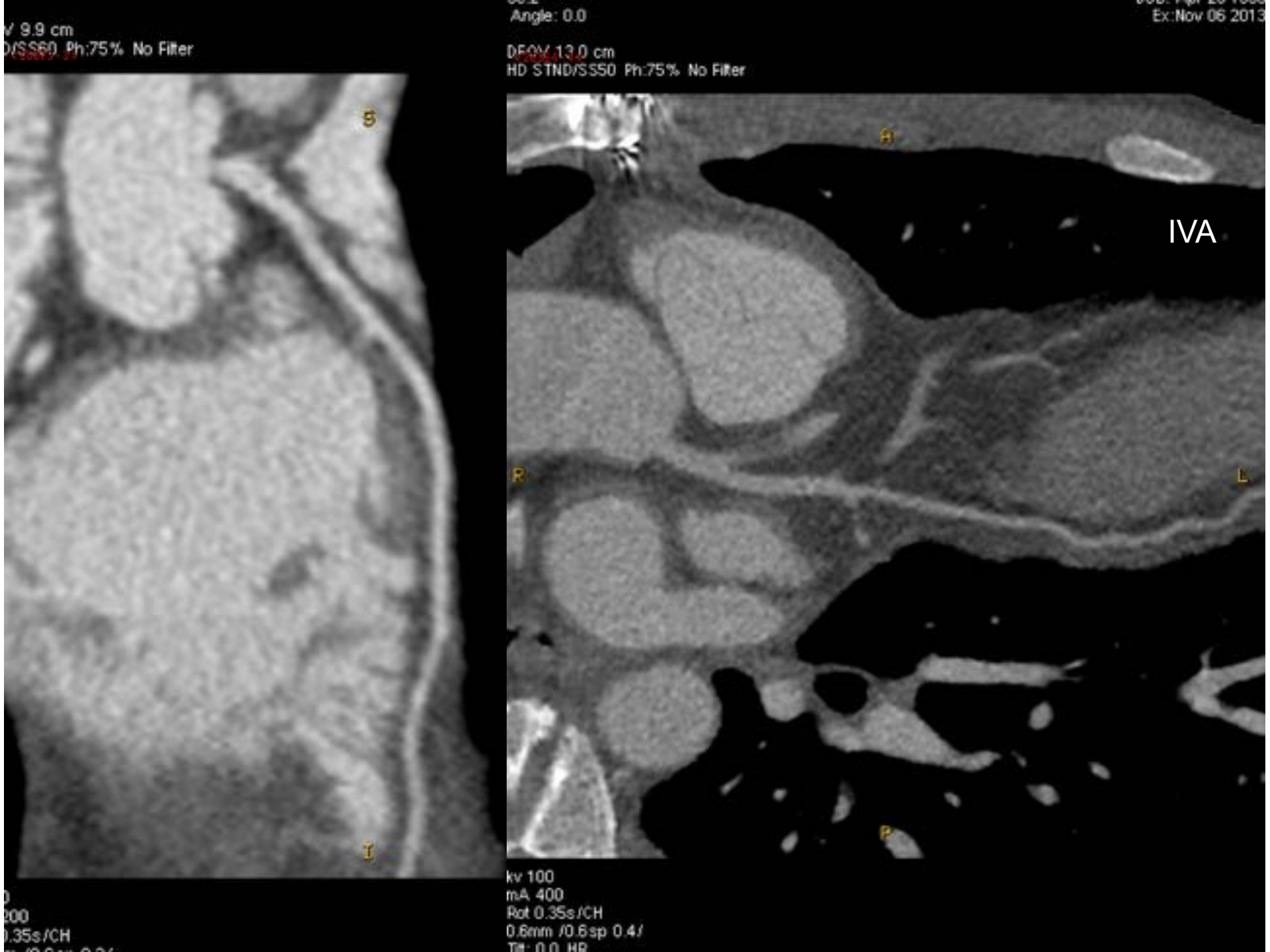
V 9.9 cm
D/SS60 Ph:75% No Filter
S
I
200
0.35s/CH
Angle: 0.0
Ex:Nov 06 2013
DFOV 13.0 cm
HD STND/SS50 Ph:75% No Filter
A
IVA
R
L
P
kv 100
mA 400
Rot 0.35s/CH
0.6mm /0.6sp 0.4/
Tilt: 0.0 HR

Se:2
Angle: 0.0
DFOV 10.1 cm
HD STND/SS50 Ph:75% No Filter
S
A
I
kv 100
mA 400
Rot 0.35s/CH
0.6mm /0.6sp 0.4/
Tilt: 0.0 HR
12:26:08 PM
P: 61.0
Branche marginale Gauche
Rfmt
3.2 mm
Marginale
Diamètre moye
Width: 2.6 cm

D/SS50 Ph:75% No Filter
TC
A
P

LP: 30.2
FOV 9.0cm
STND/SS50 No Filter Ph:75%
CD+Cx

3D2
Ex: 219
Se: 3 +c
Volume Rendering: No cut
DFOV 20.0cm
STND Rh75% (No Filt.)
SPR
HOPITAL NECKER ENFANT
R
A
S
L
P
I
No VOI
kv 120
mA 499
Rot 0.35s/CW 10.4mm/rot
0.6mm 0.26:1/0.6sp
Tilt: 0.0
12:01:12 PM
W = 4095 L = 2048
IAL

7.7 mSv

0.5 mSv

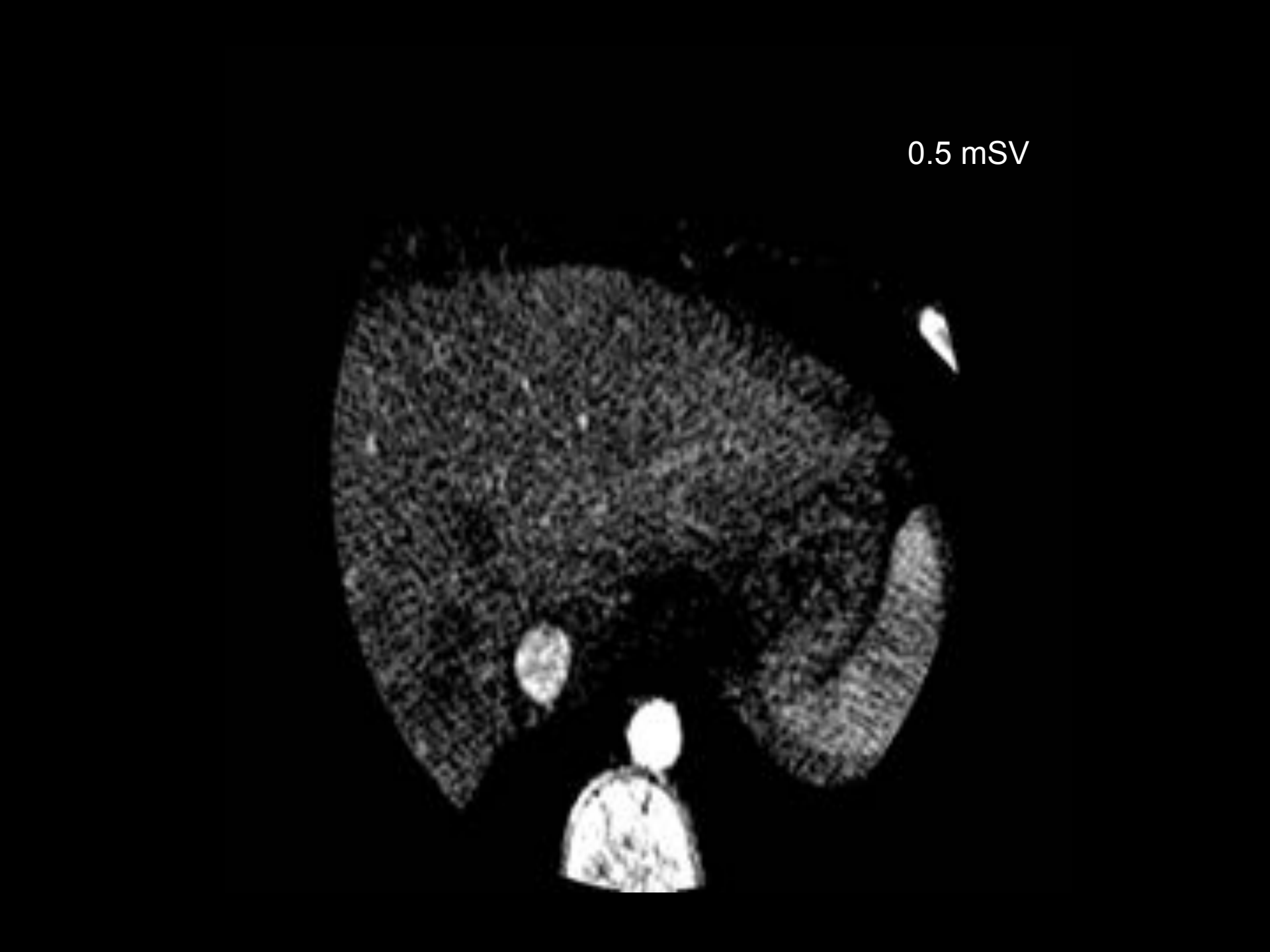
0.5 mSV

IRM - 3D avec double gating

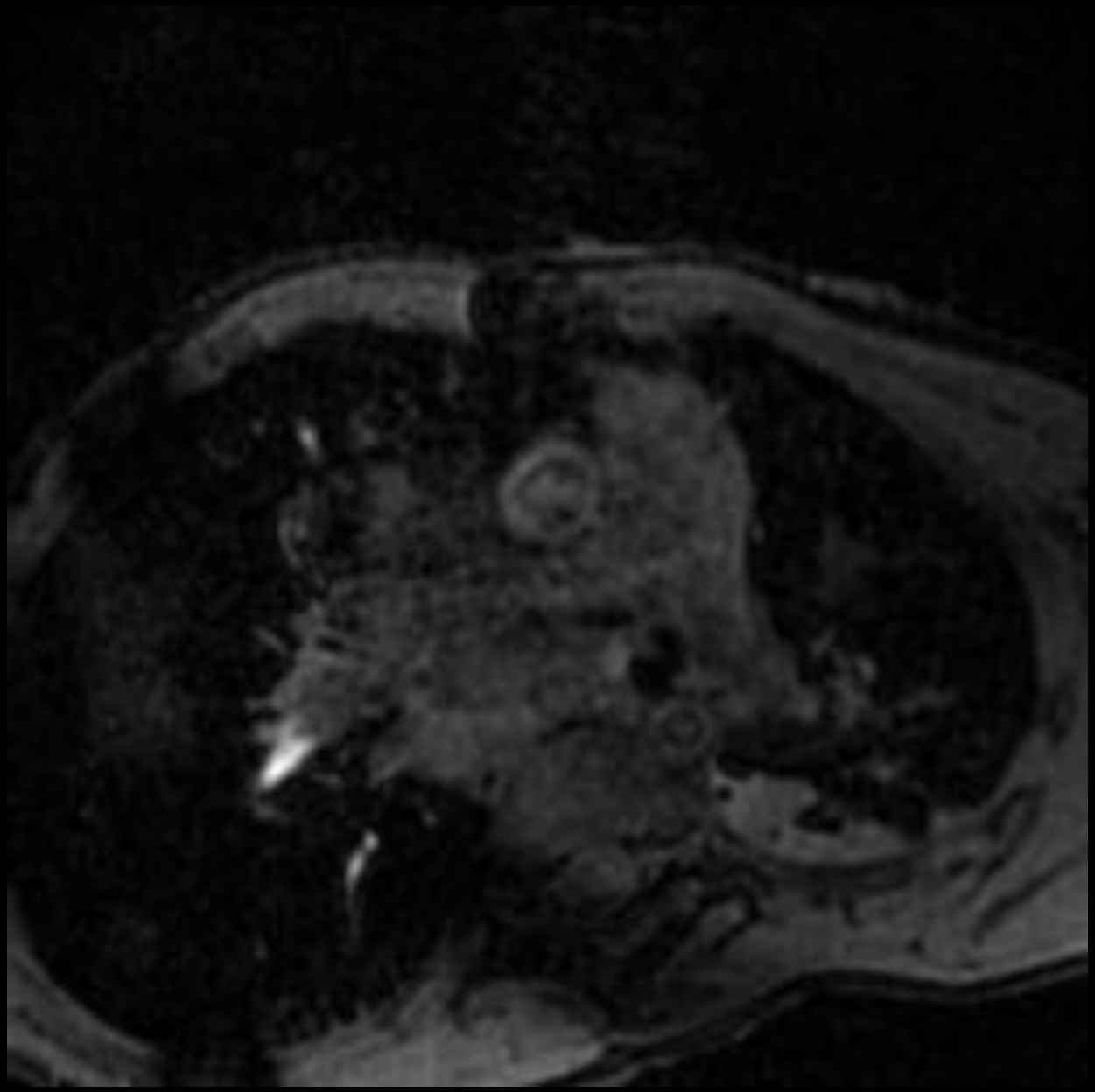

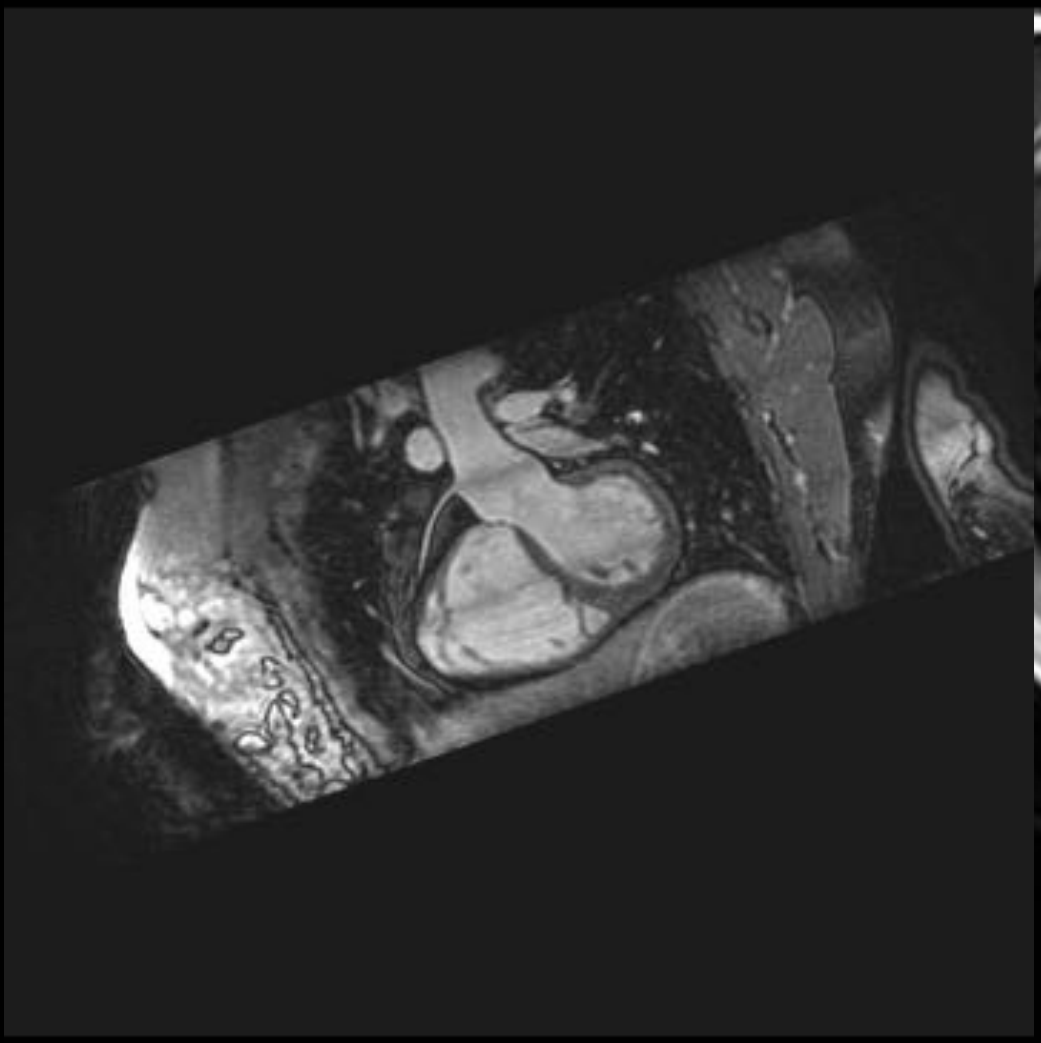

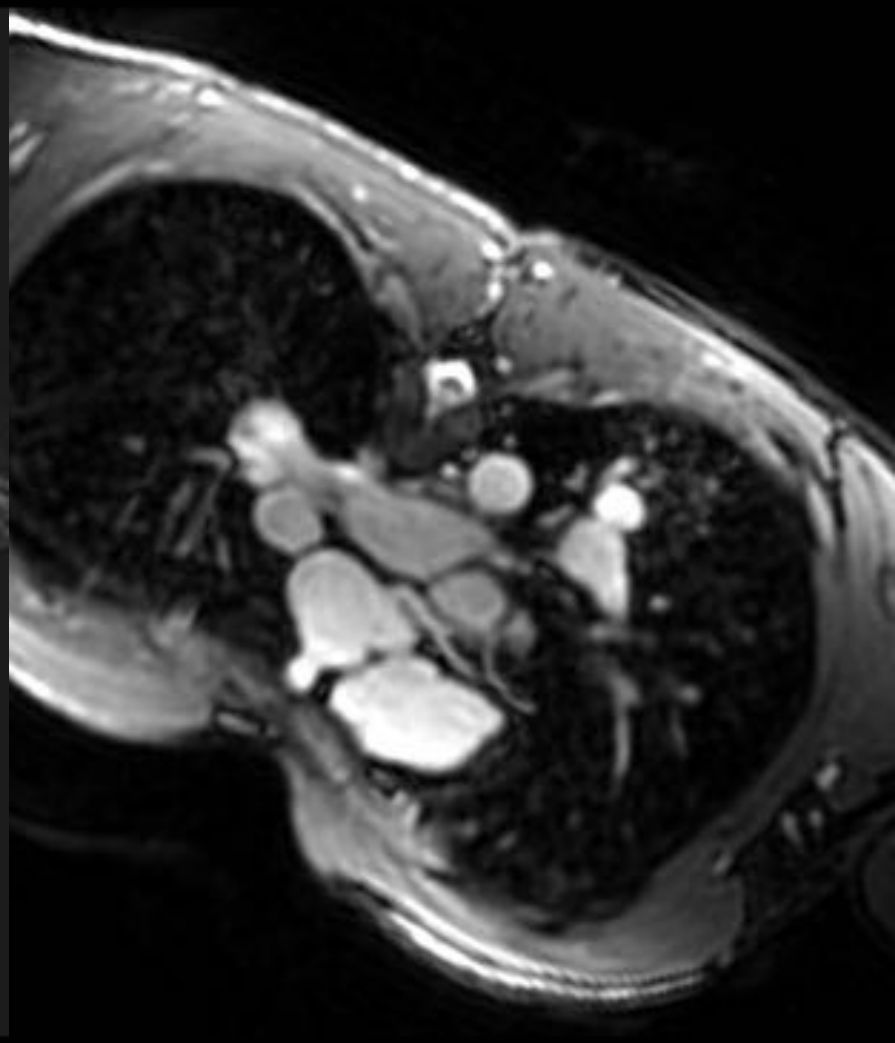

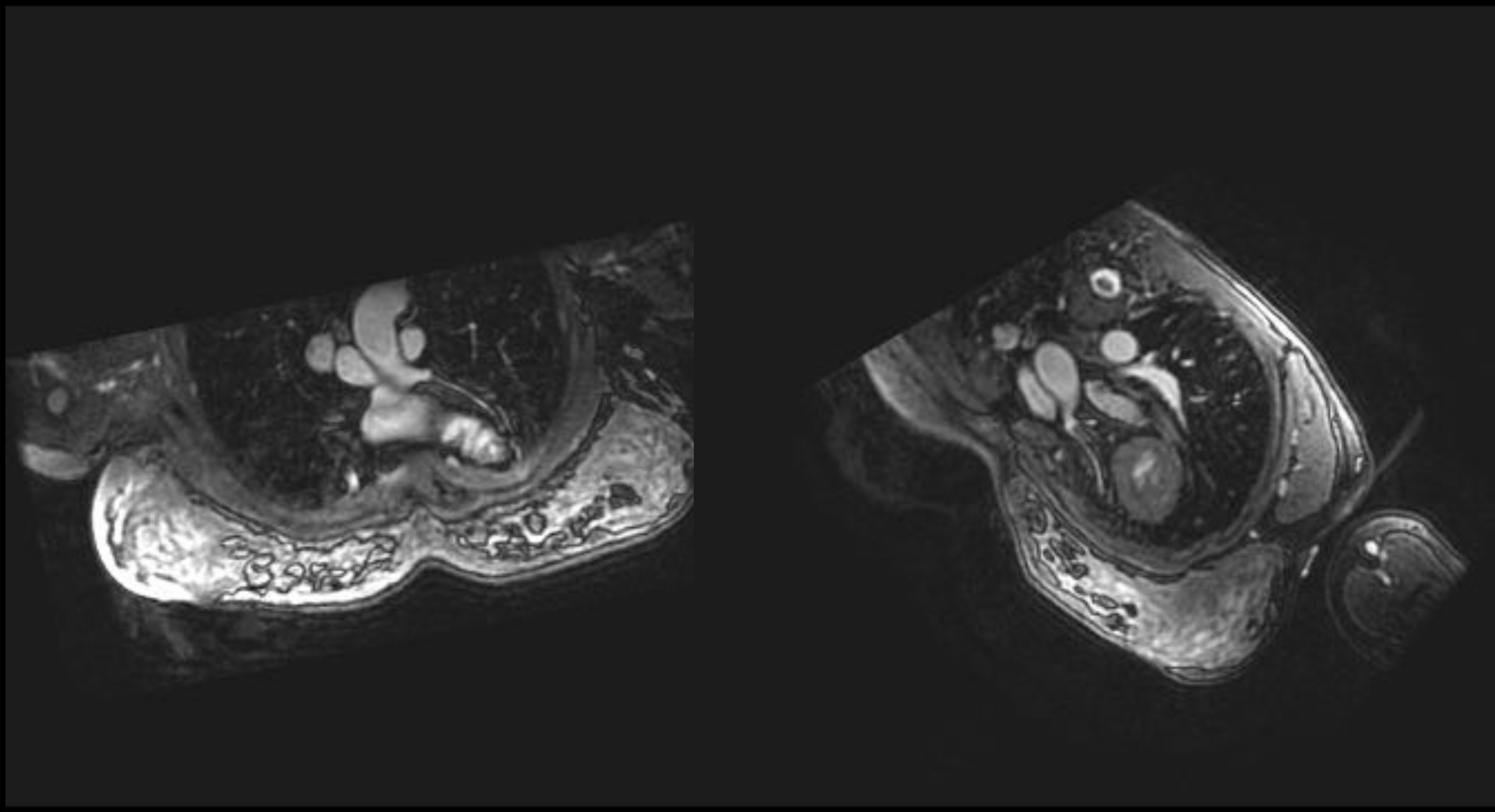

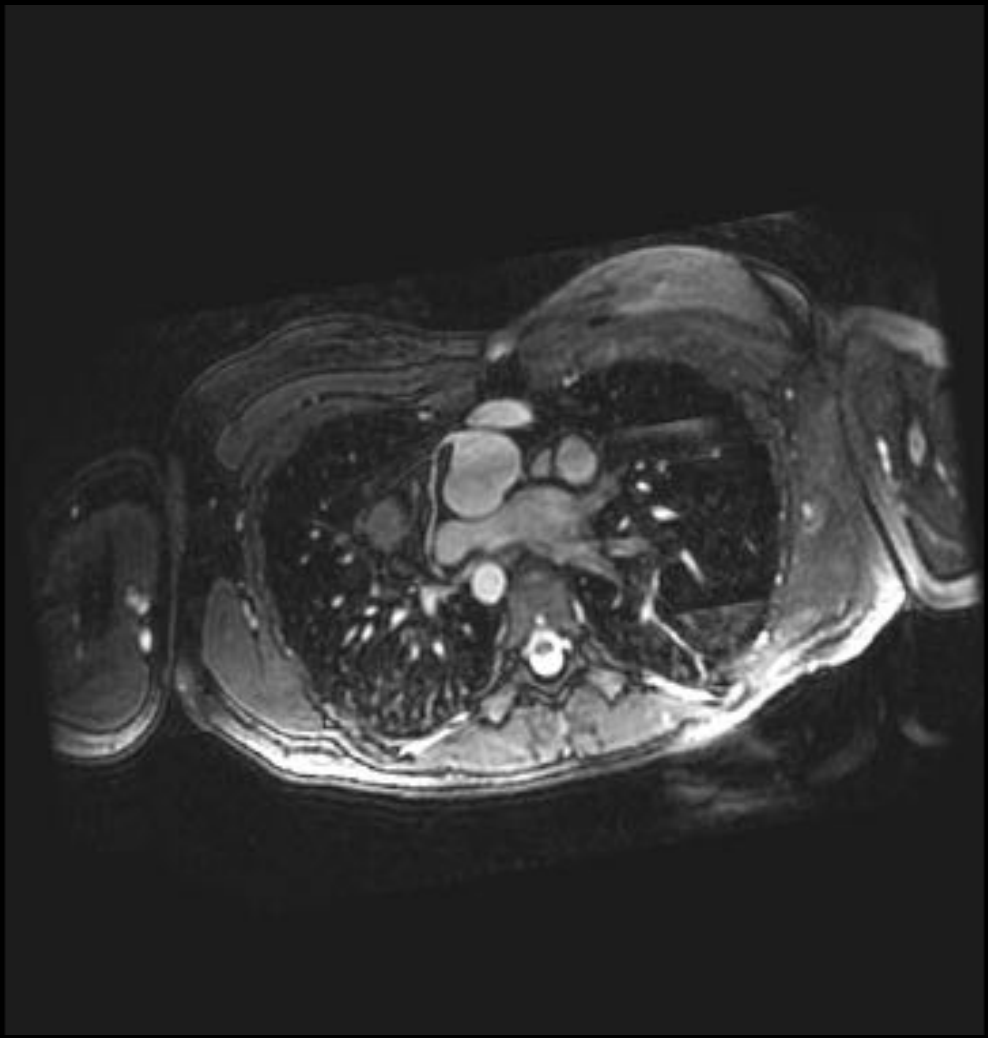

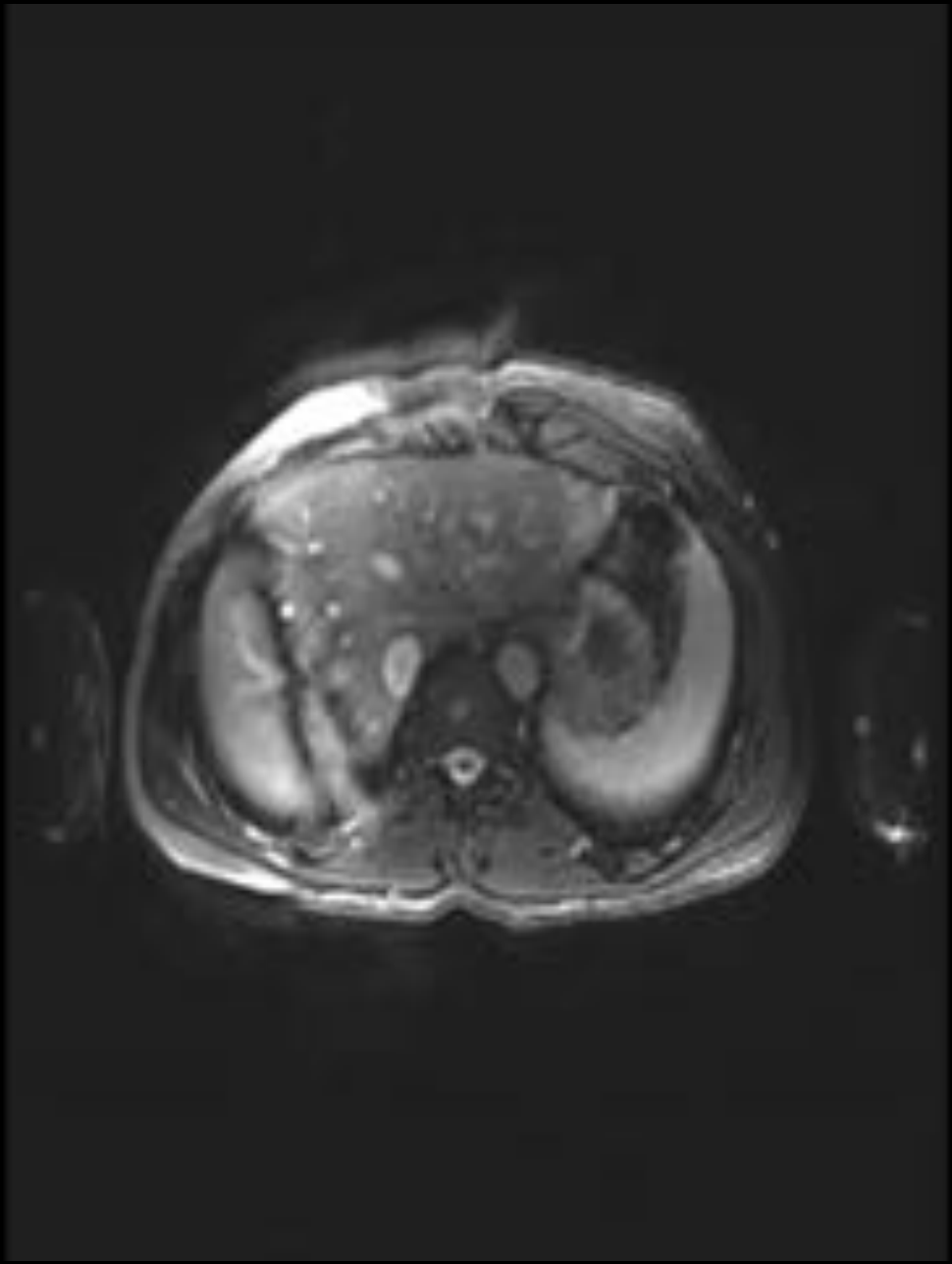

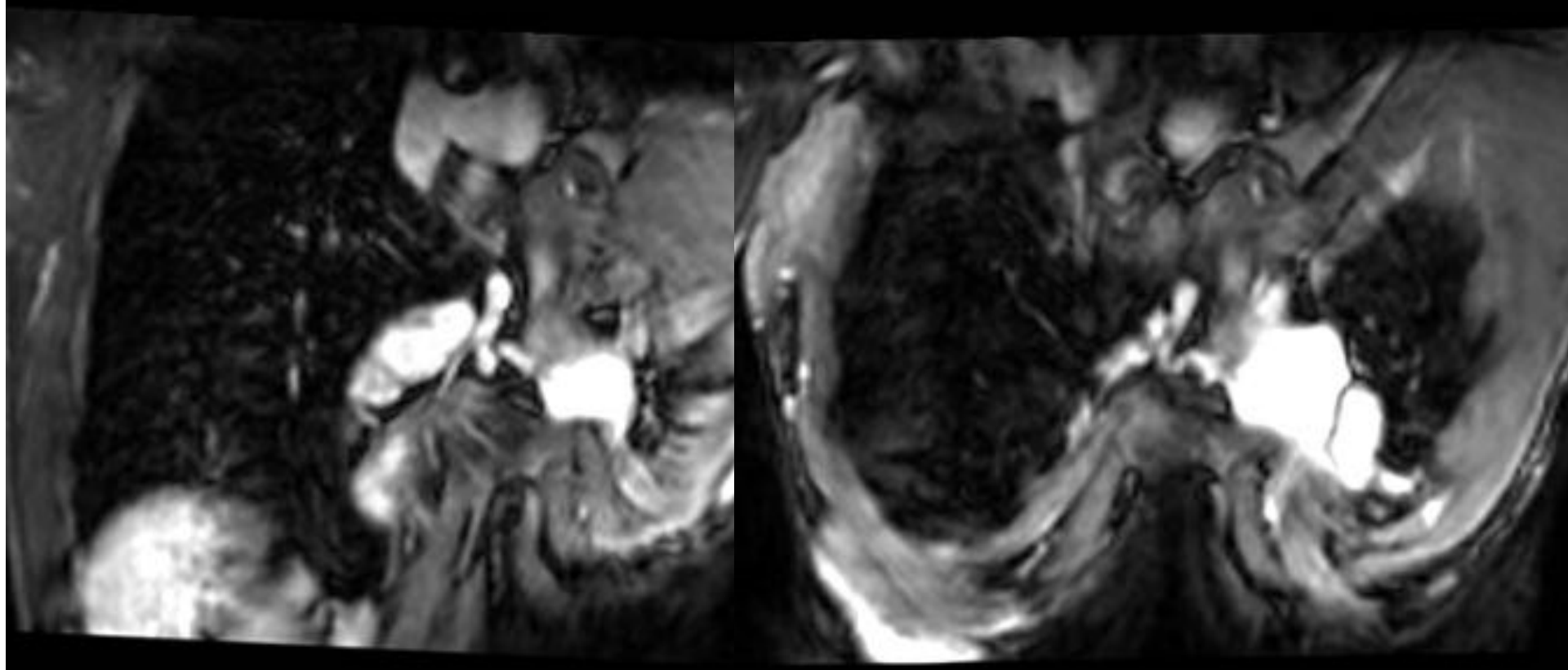

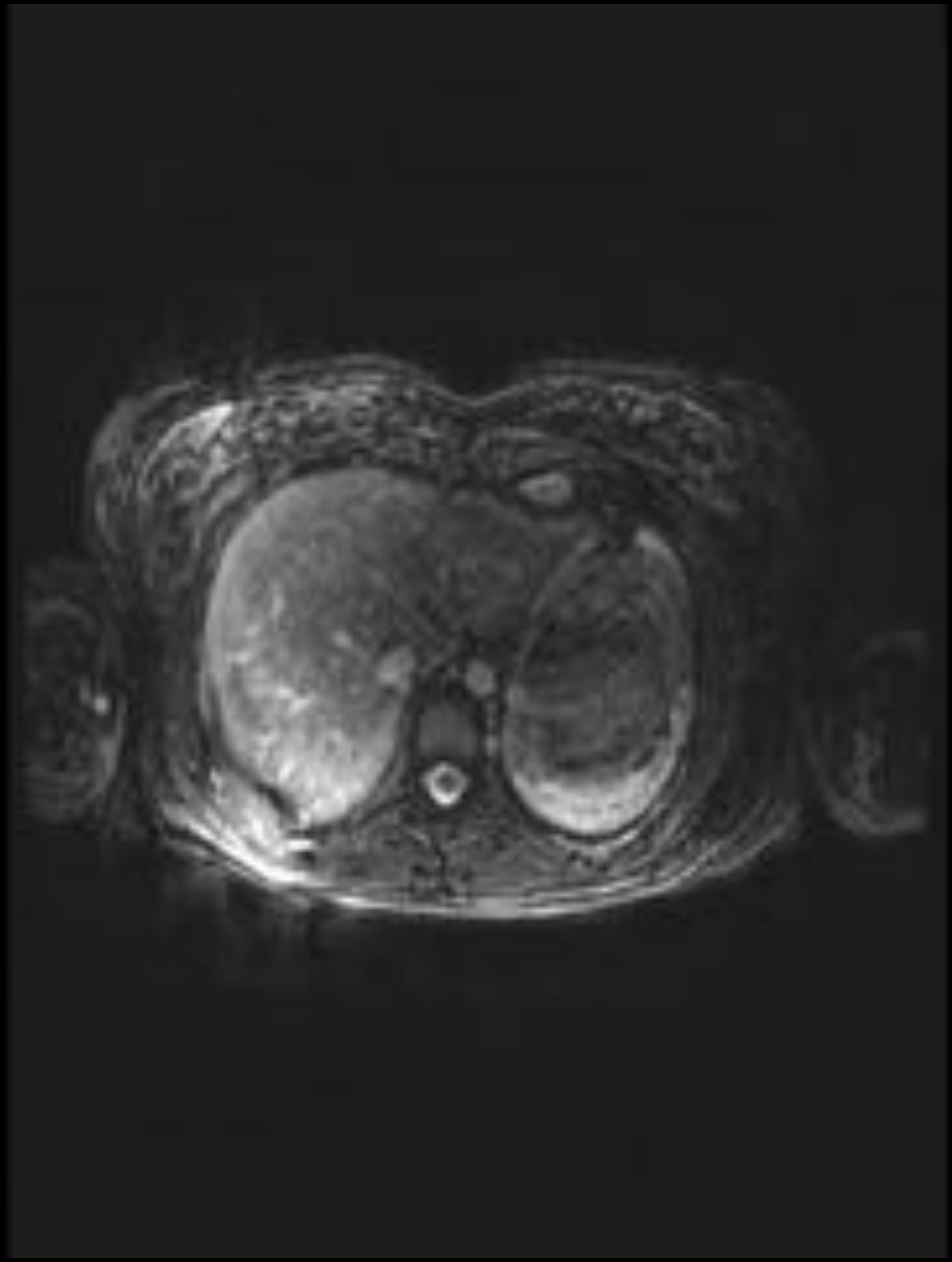

Indications Scanner

Anatomie

- Détails anatomiques dans les pathologies des gros vaisseaux et rapport avec les bronches

e Rendering No cut
DoB: Sep 18
Ex:Nov 06
14.0 cm
SS50 No Filter
I
9
.40s/HE• 55.0mm/rot
1.375:1/0.6sp

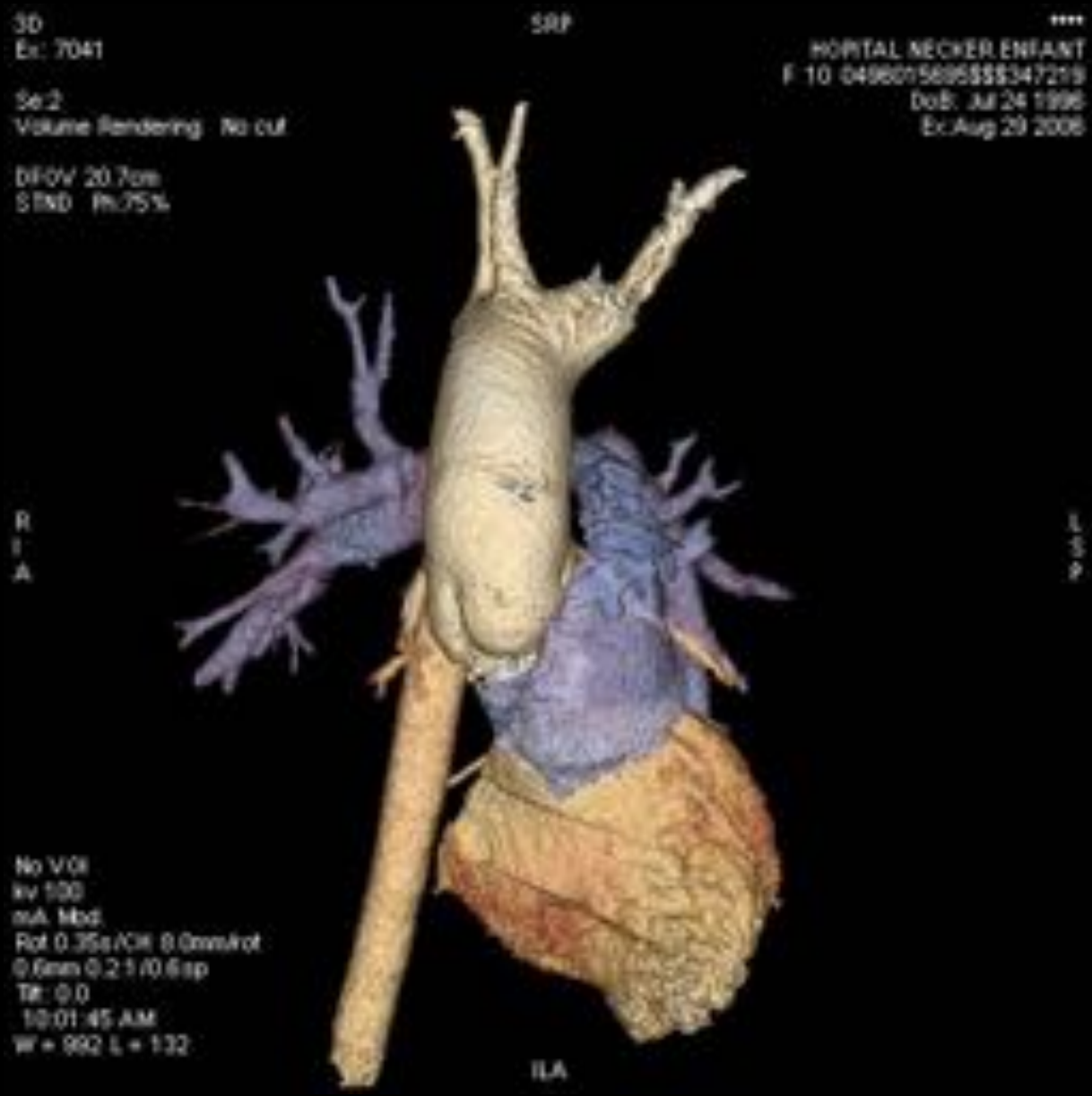
3D
Ex: 7041
Se:2
Volume Rendering No cut
DFOV 20.7cm
STND Rh:75%
SRP
****
HOPITAL NECKER ENFANT
F 10 0498015689$$$$347219
DoB: Jul 24 1996
Ex:Aug 29 2006
R
I
A
L
S
P
No VOI
kv 100
mA Mod.
Rot 0.35s/CR 8.0mm/rot
0.6mm 0.2:1/0.6sp
Tilt: 0.0
10:01:45 AM
W = 992 L = 132
ILA

Indications Scanner

Anatomie

- Etude des collatérales aorto-pulmonaires dans l'APSO

Anatomie complexe

Anatomie complexe

Anatomie intracardiaque

Anatomie complexe

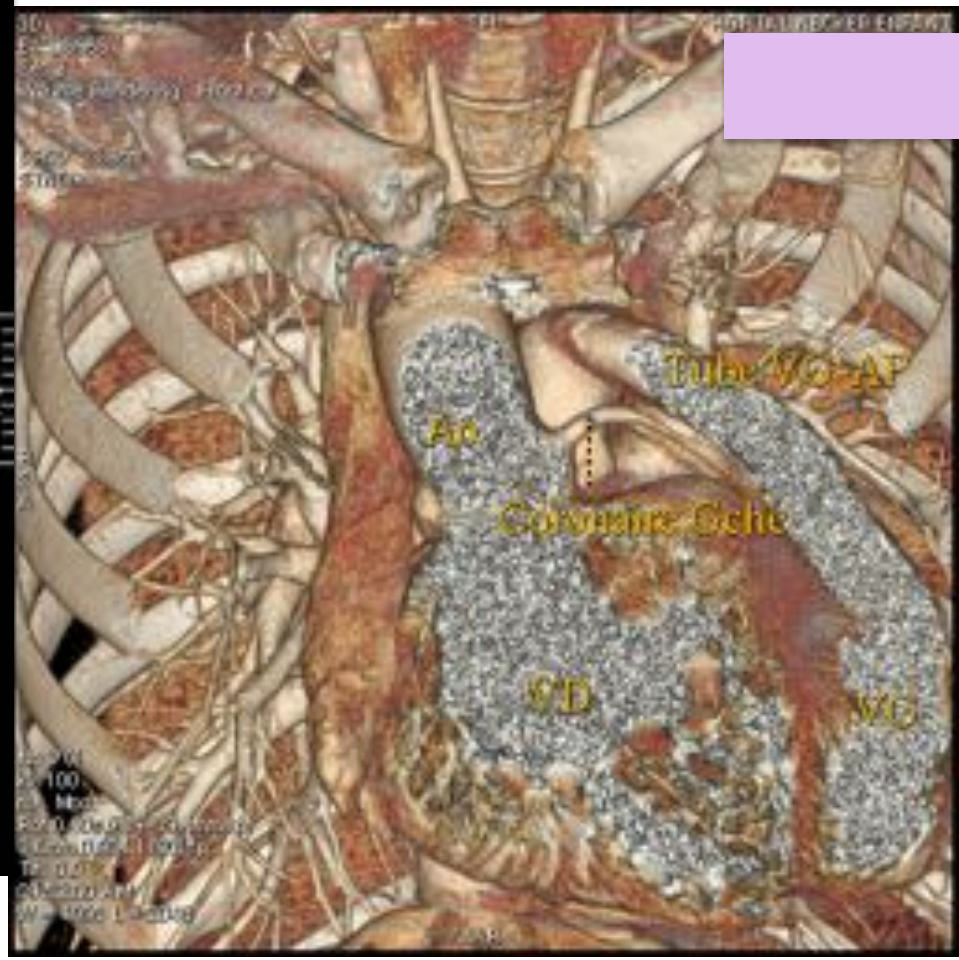

RVPA

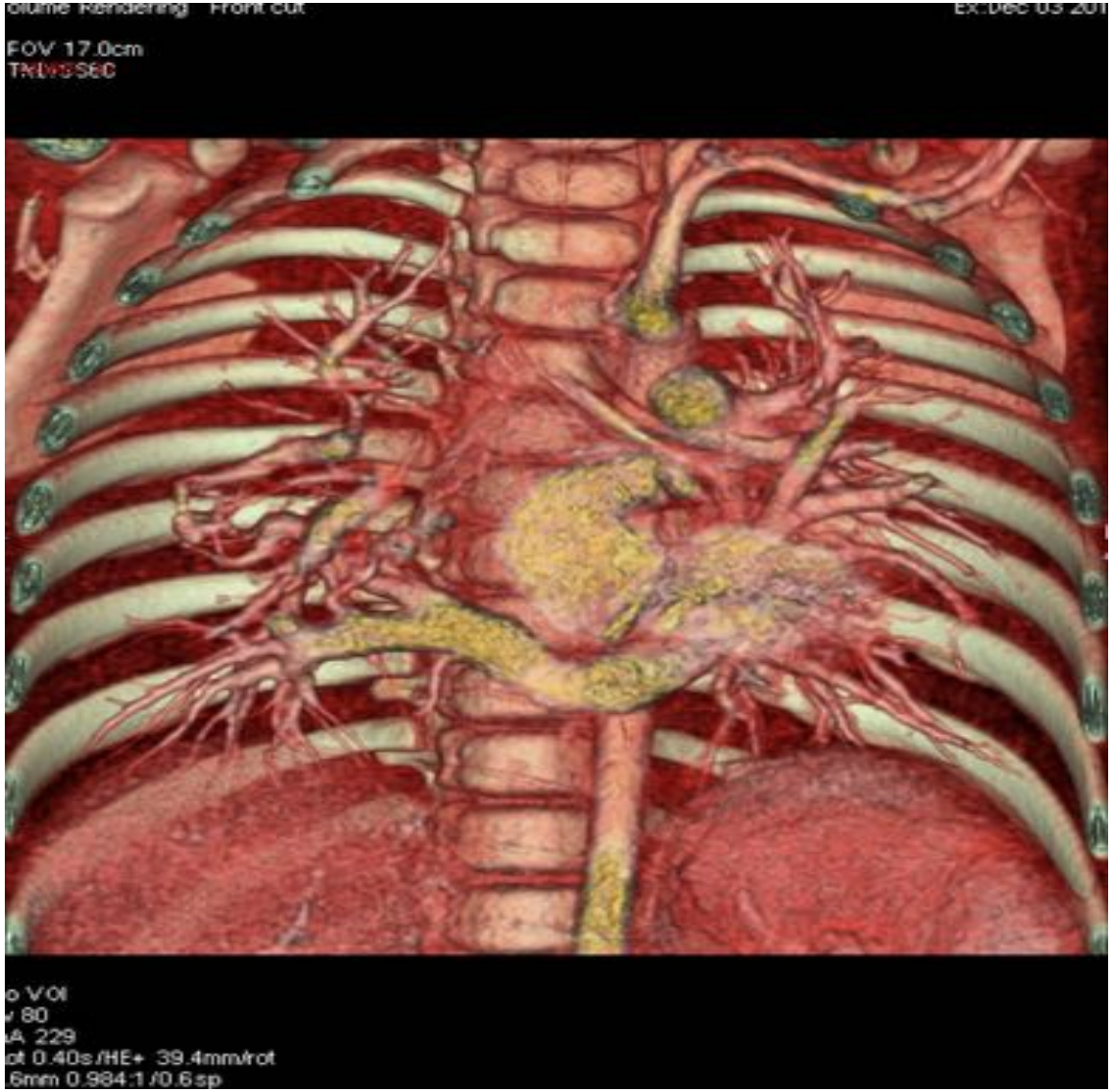

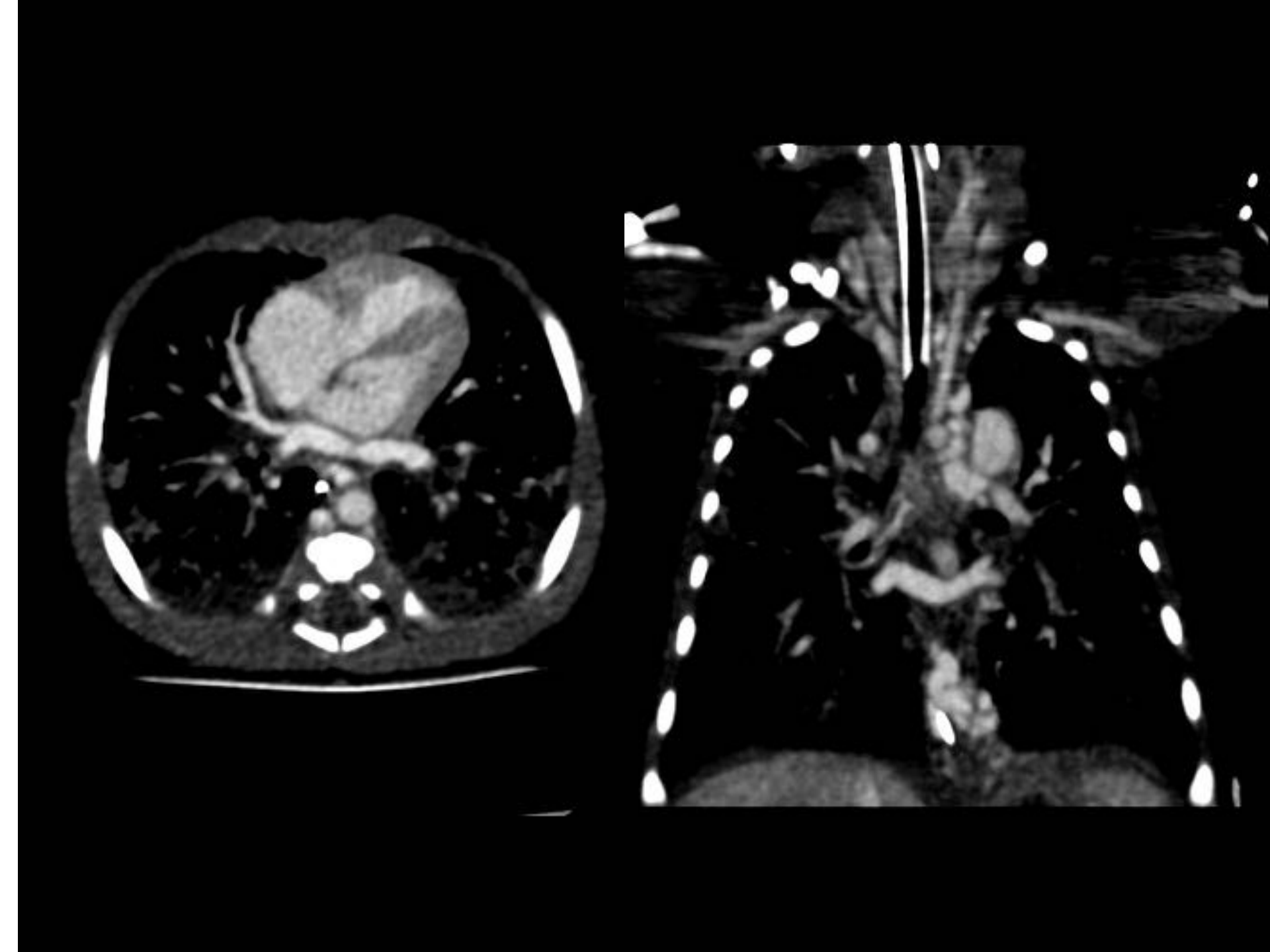

Indications Scanner

Anatomie

- Etude du parenchyme pulmonaire

20677 - 1 >

< 20677 - 2 >

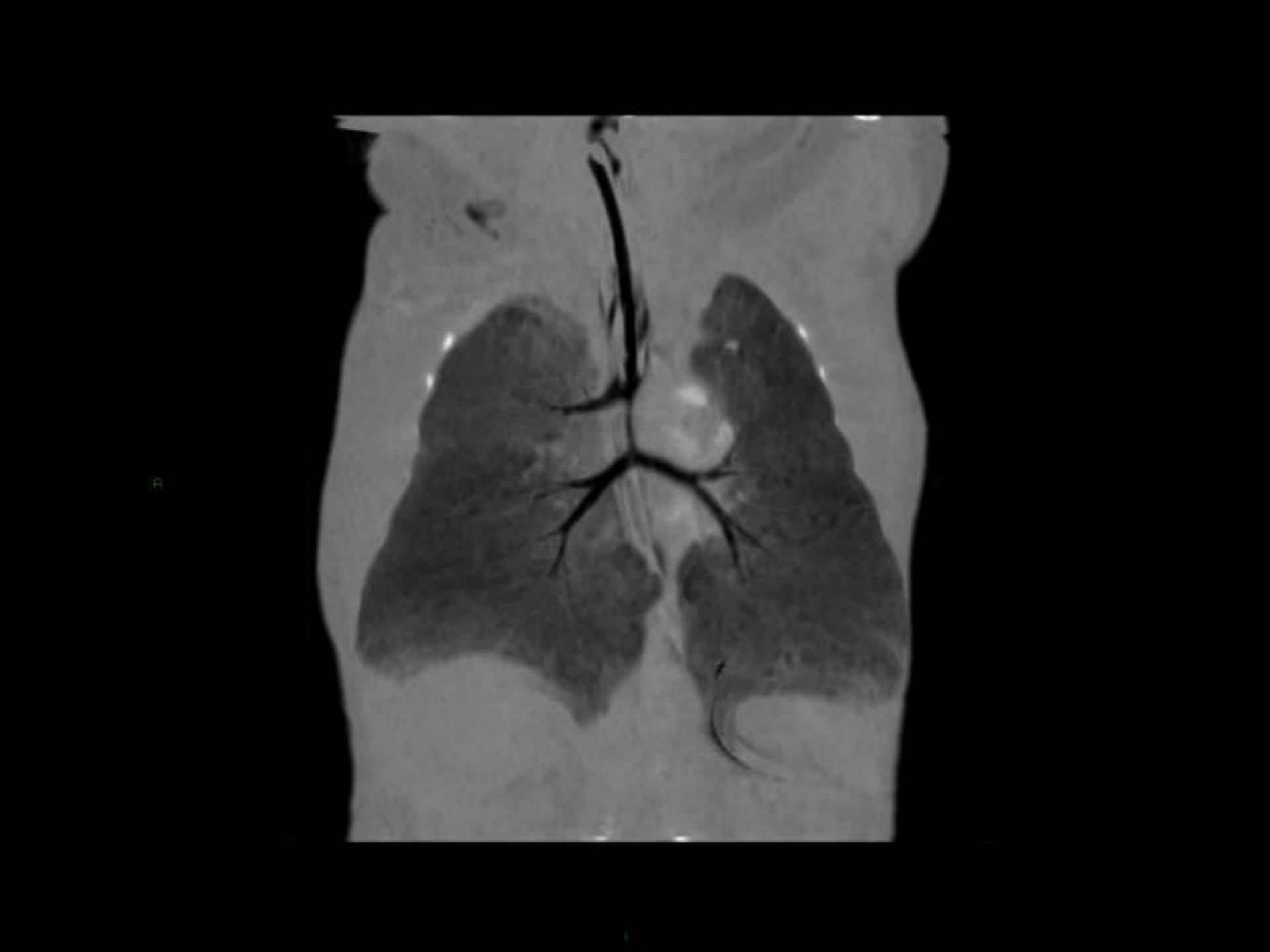

Indications IRM

- **Morphologie, fonction et analyse tissulaire**
  - Morphologie, Volumes, Masses, Fonction des ventricules
  - Fonction des Valves cardiaques
  - Perfusion myocardique/réserve coronaire/réserve contractile
  - Perfusion pulmonaire
  - Etude du myocarde: inflammation/fibrose

Morphologie et fonction

Anatomie

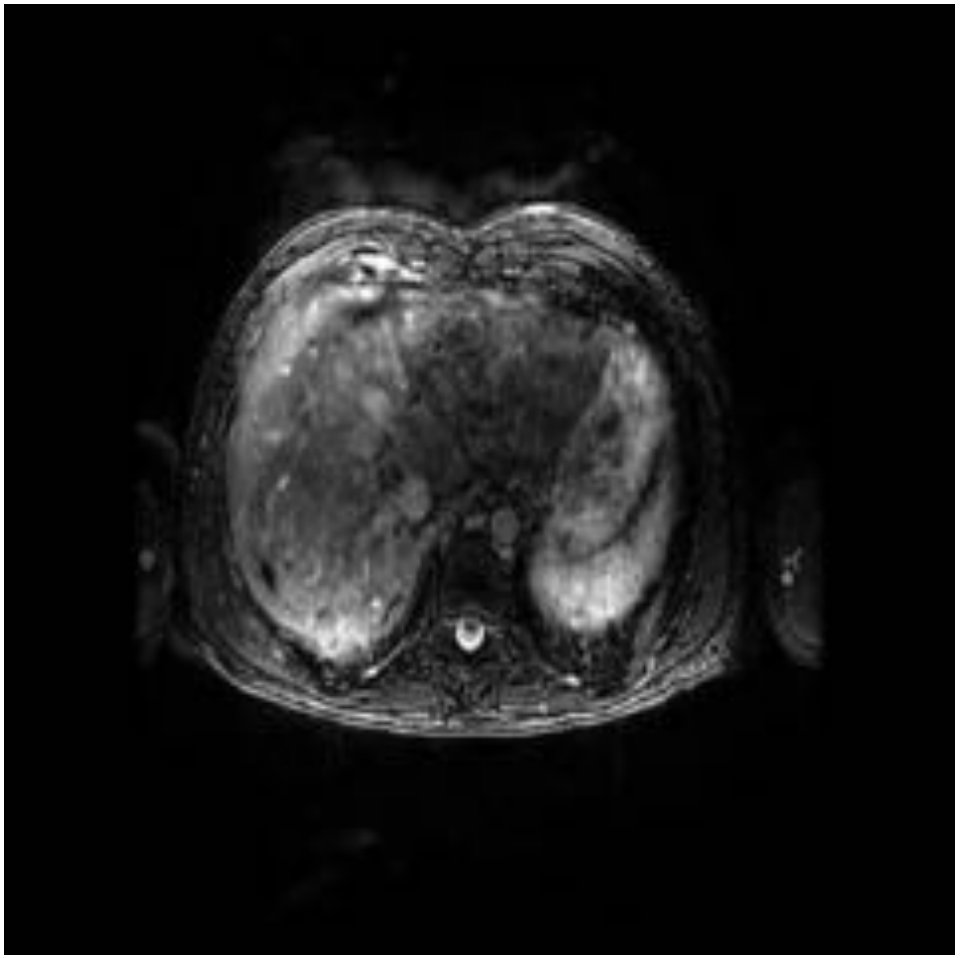

Anatomie

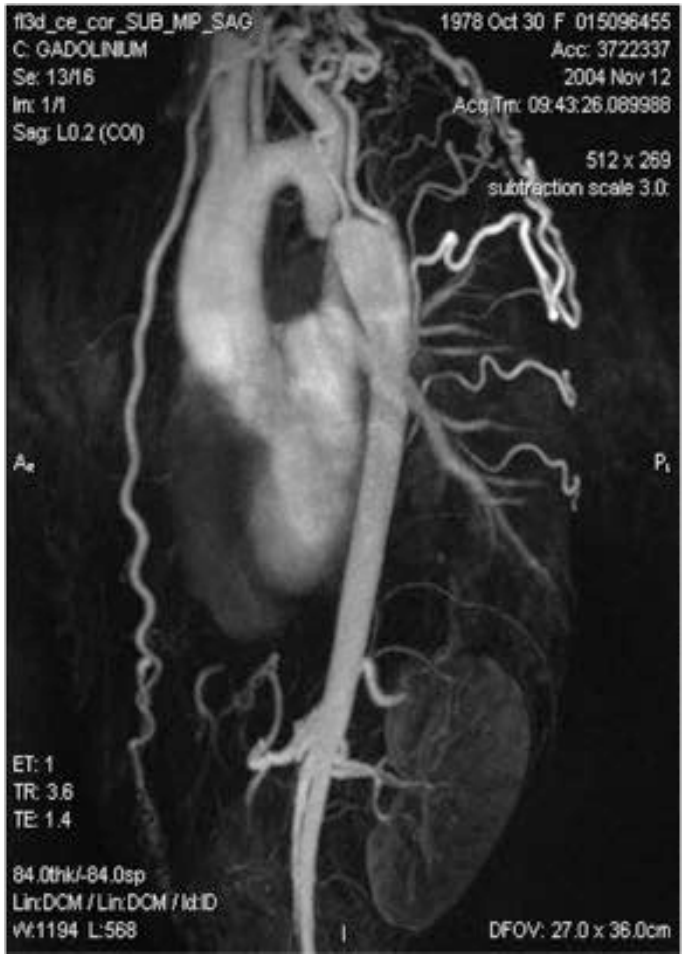
fl3d_ce_cor_SUB_MIP_SAG
C: GADOLINIUM
Se: 13/16
Im: 1/1
Sag: L0.2 (COI)
1978 Oct 30 F 015096455
Acc: 3722337
2004 Nov 12
Acq Tm: 09:43:26.089988
512 x 269
subtraction scale 3.0:
ET: 1
TR: 3.6
TE: 1.4
84.0thk/-84.0sp
Lin:DCM / Lin:DCM / Id:ID
W:1194 L:568
DFOV: 27.0 x 36.0cm

3D MIP/TOF/FSPGR Phase 1
Ex: 10359
SFL
Se:10 ms
Volume Rendering Mode:cut
Ex:Oct 19 2013
1.41 x
SFOV 25.5 cm
ET:1
No VOI
MIP/TOF/FSPGR
TR:4.1
TE:1.5/Fr
EF:1/1 62.5kHz
1081/1
32Ch Cardiac/
00:50
2.0mm /1.0sp
288/192/0.74 MEX
FAST_GDMS\MP_GDMS\ACC_GDMS\VASCTOF_GDMS\FFT\FFT
W = 6300 L = 3168
SFL

Anatomie

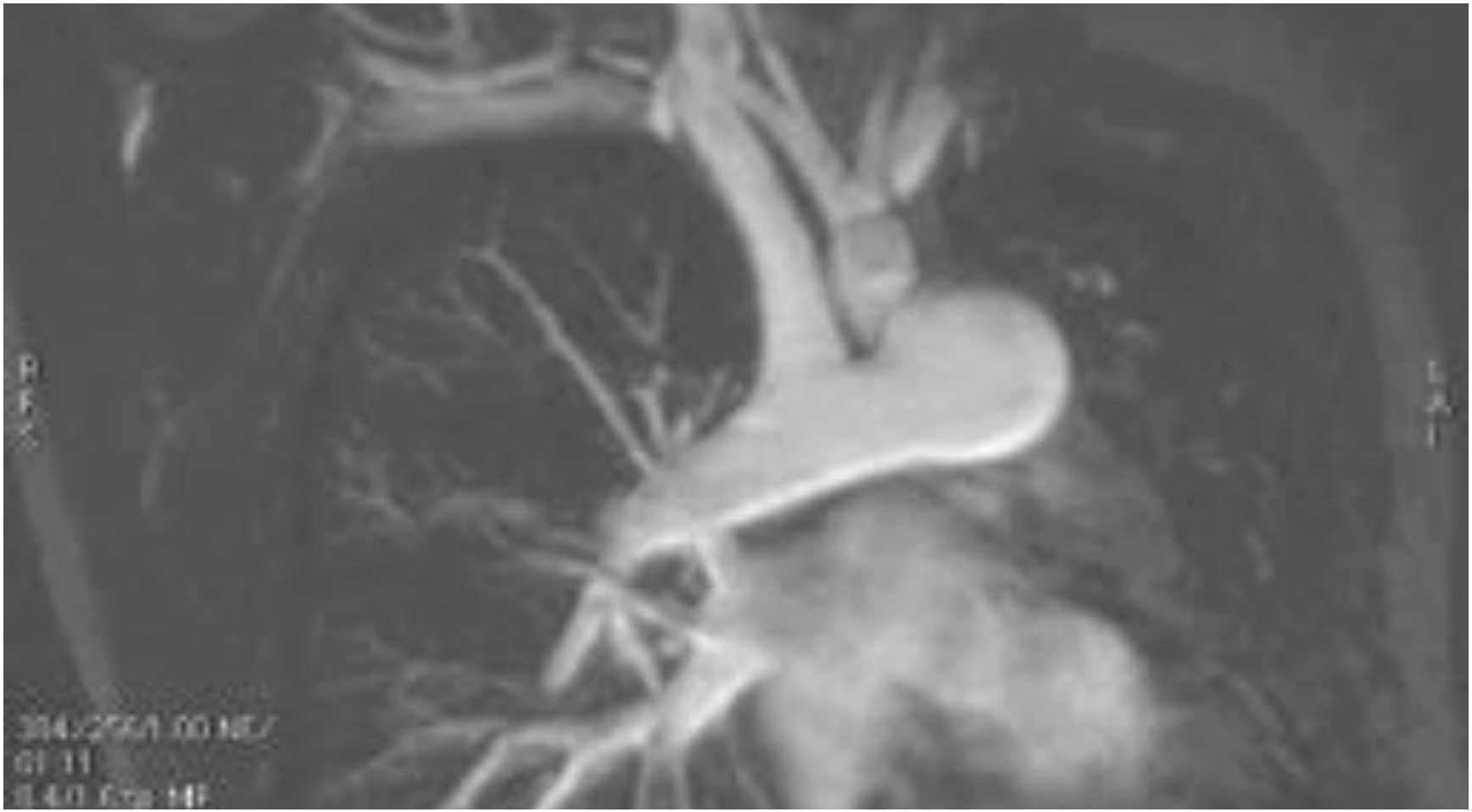

Anatomie

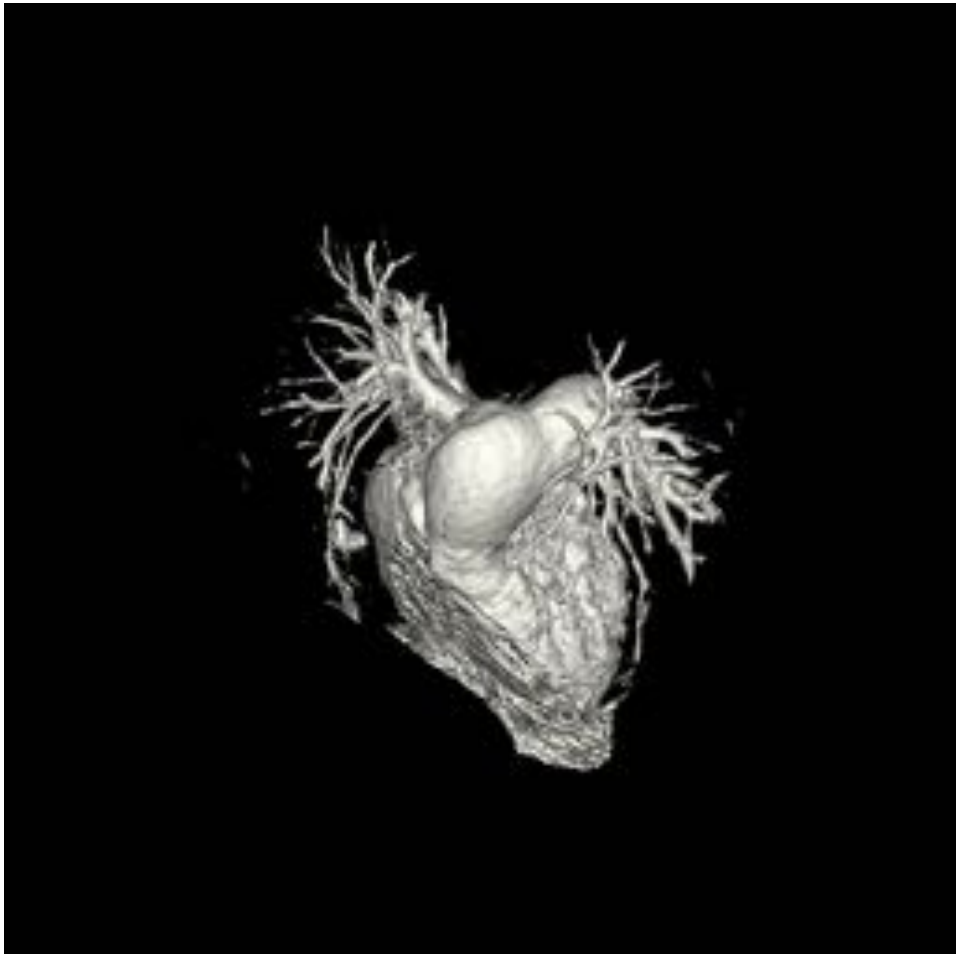

Anatomie

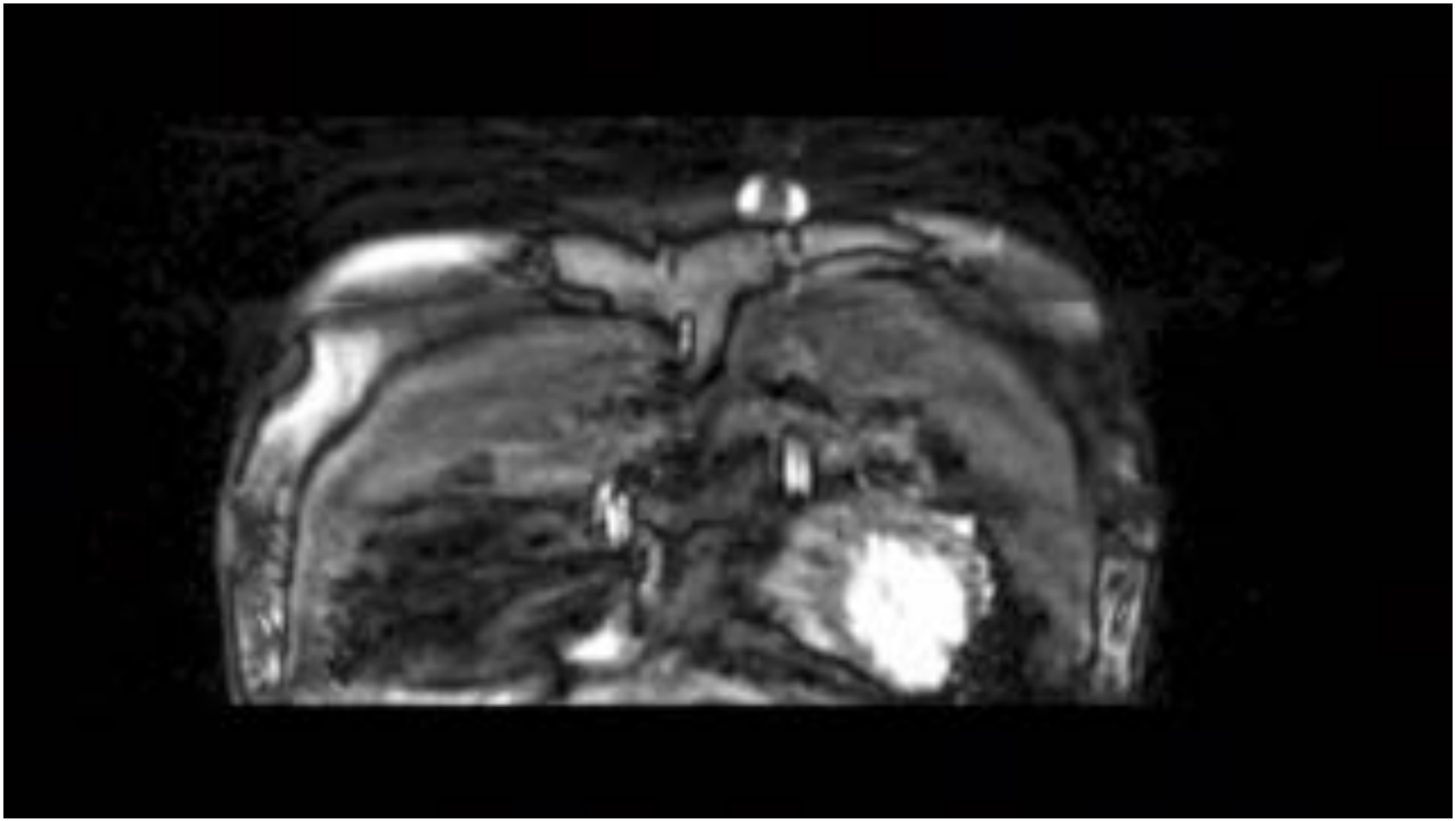

Anatomie

3D
SRP
Volume Rendering No cut
R
P
I
L
A
S
No VOI
4.4mm /1.1sp
DFOV 30.0cm
W = 4095 L = 2048
ILA

Anatomie

Surface
SAL
Volume Rendering No cut
L
I
A
R
S
P
No VOI
3.0mm /1.9sp
DFOV 22.3 cm
W = 462 L = 209
IPR

Volumes-Fonction

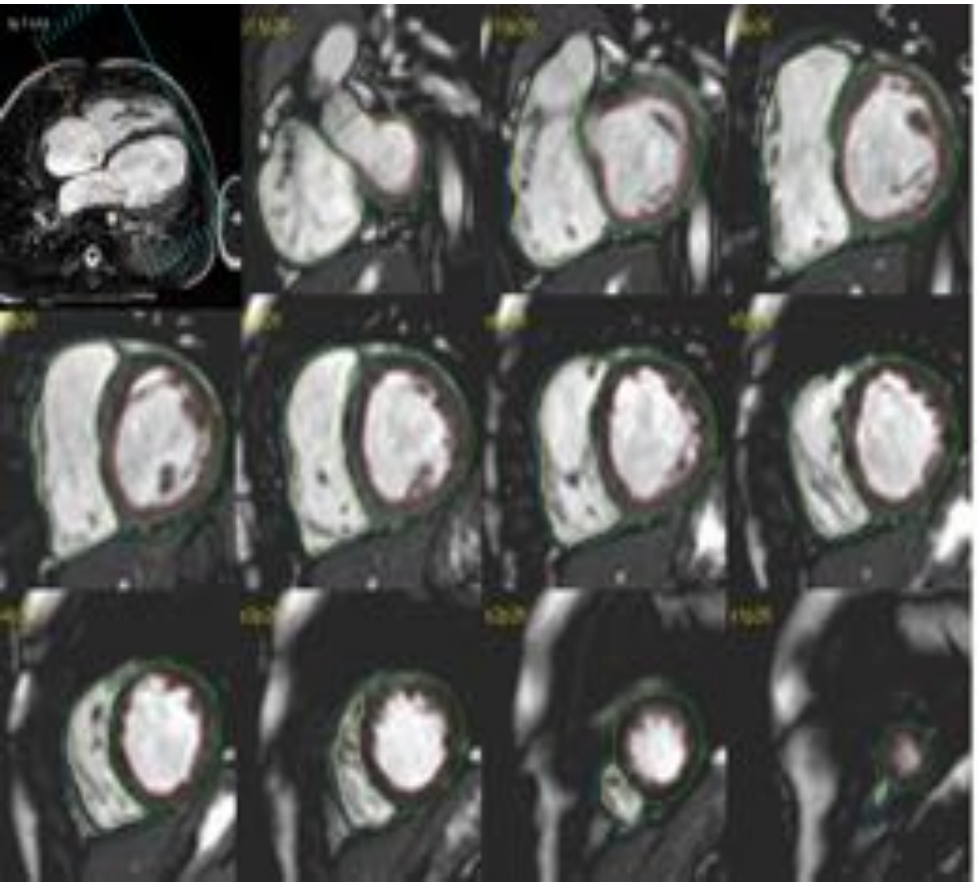

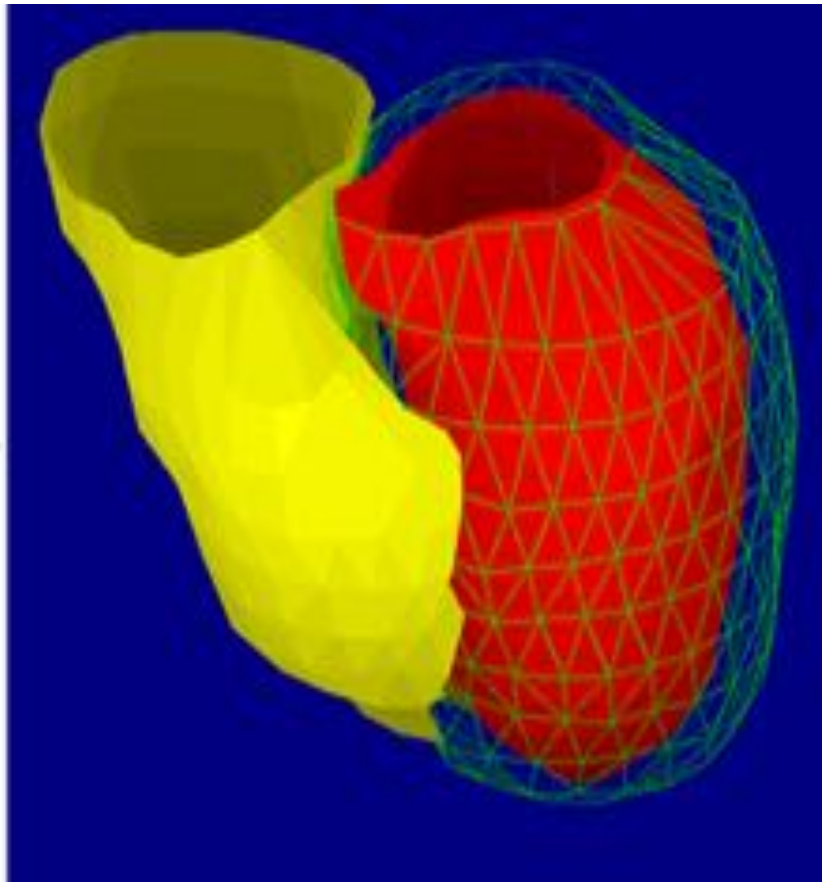

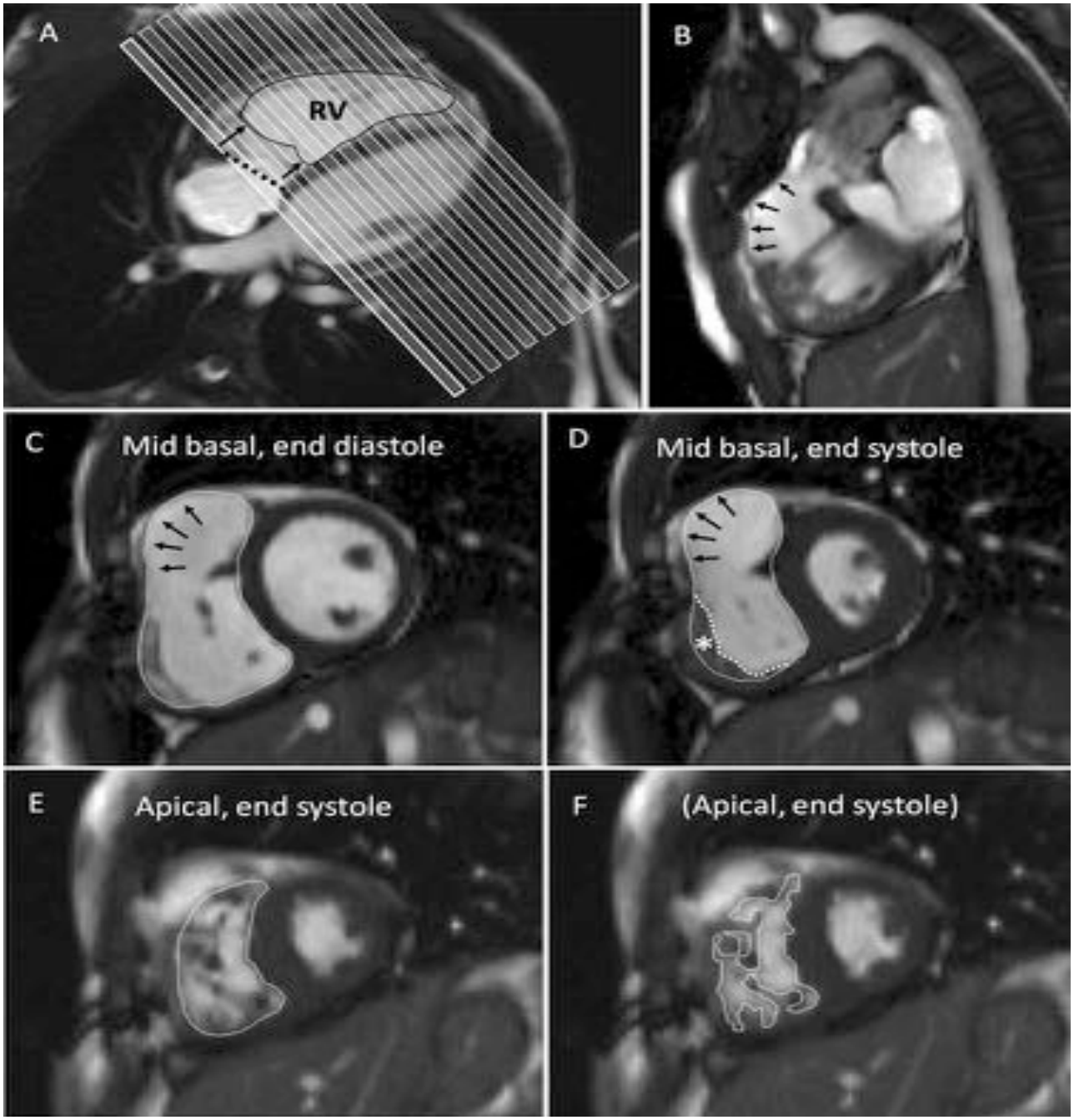
A
RV
B
C
Mid basal, end diastole
D
Mid basal, end systole
E
Apical, end systole
F
(Apical, end systole)

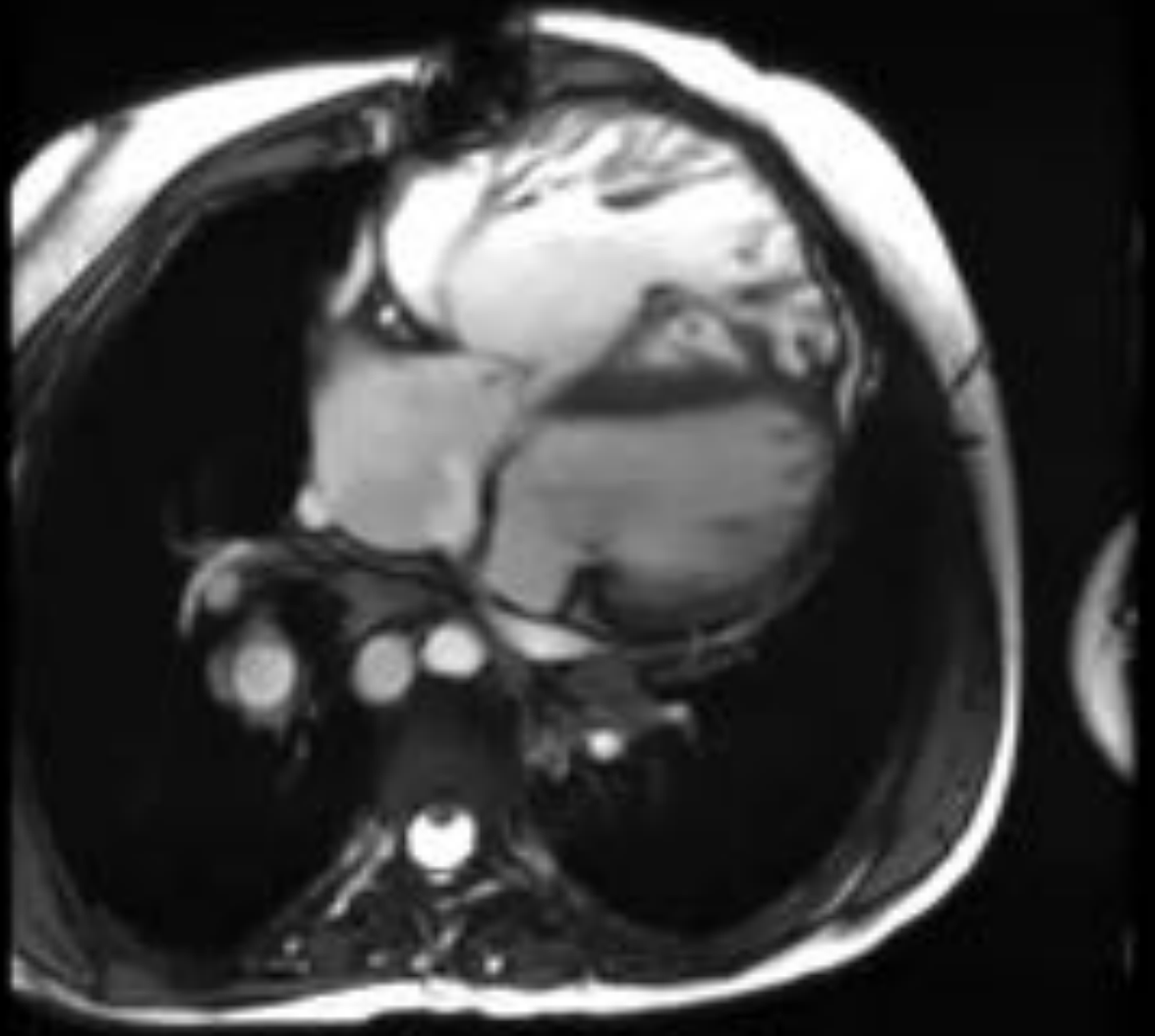
WW: 2000 WL: 1000

VD systémique / Mustard

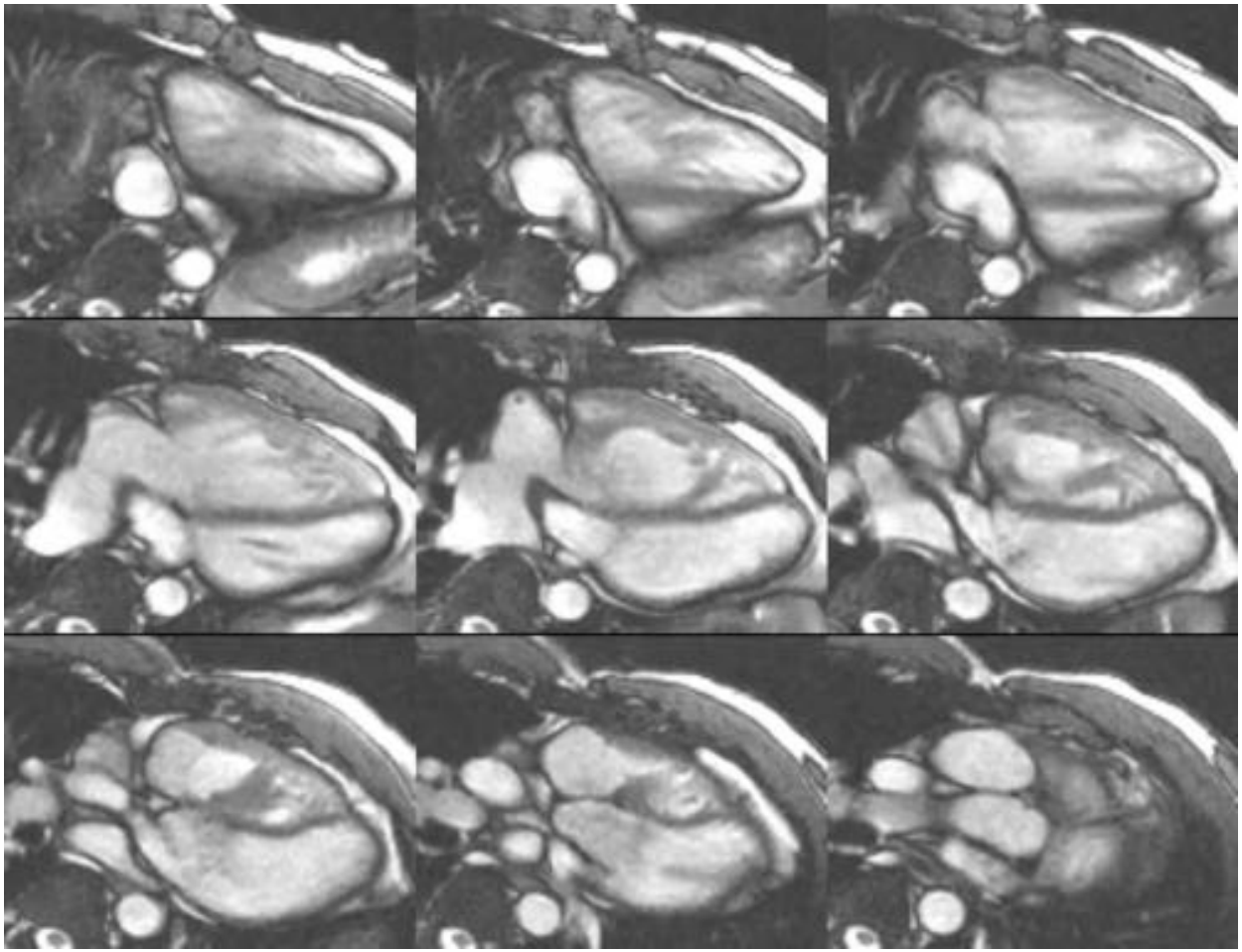

VD systémique / Mustard

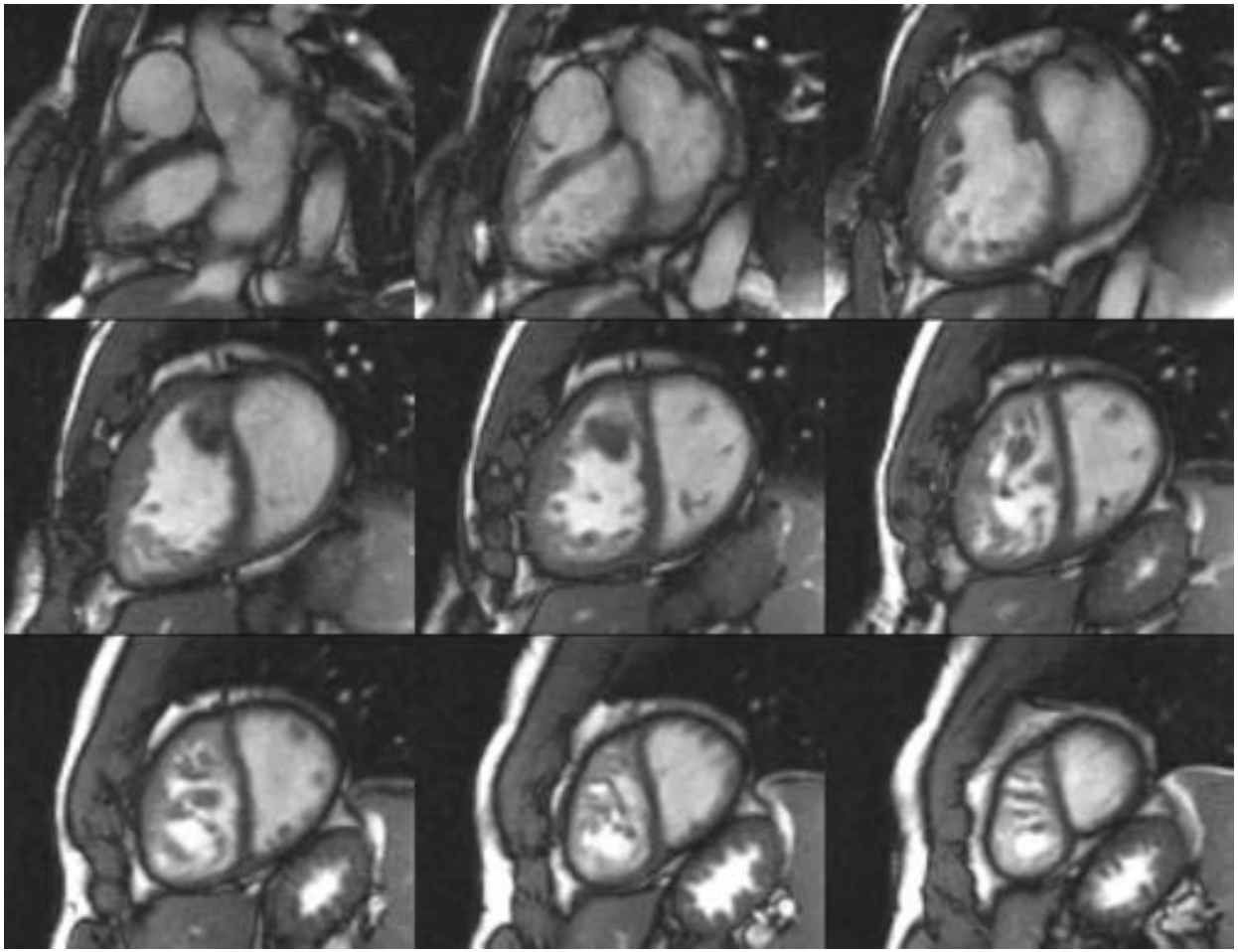

Rastelli

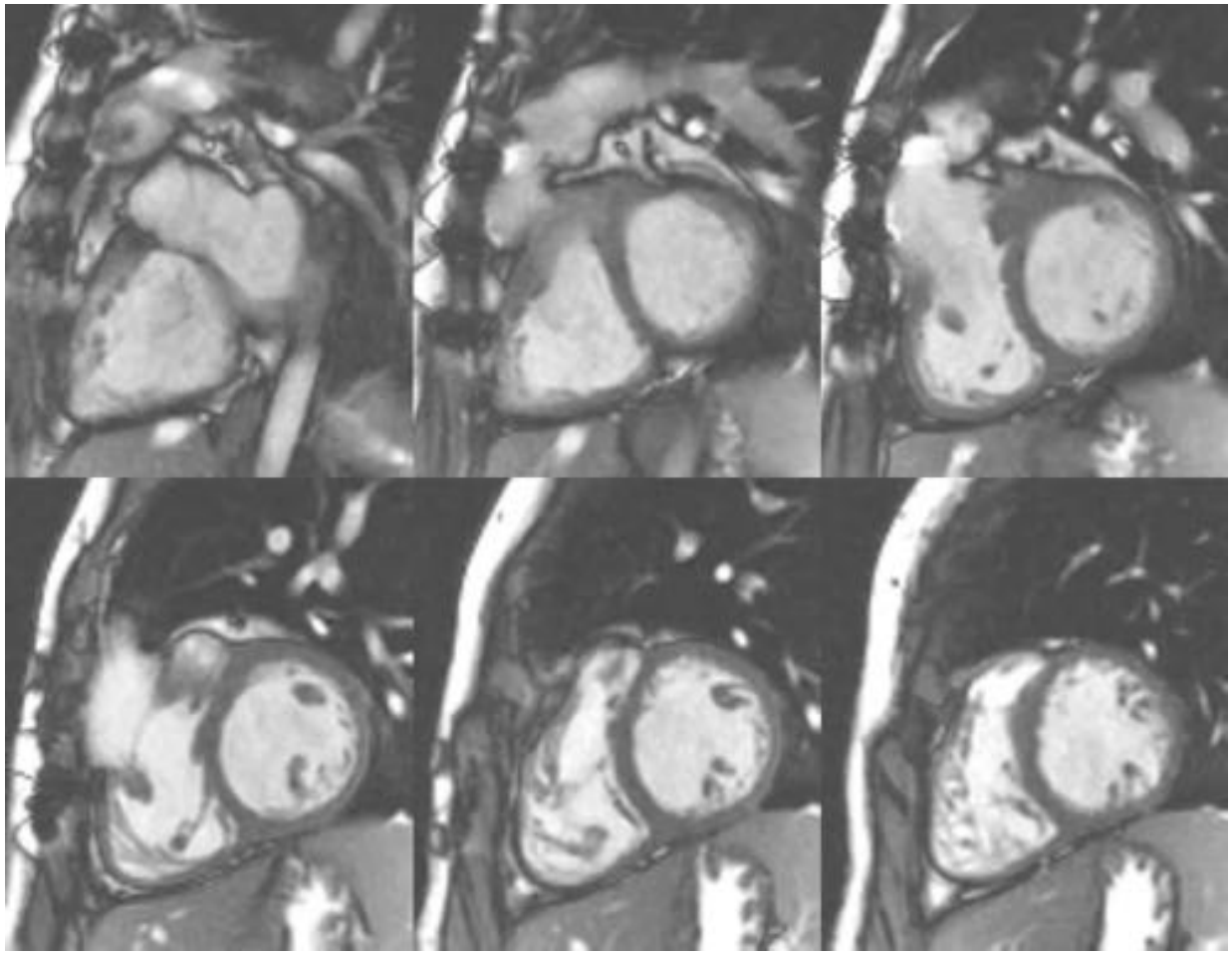

Chenaux atriaux / Mustard

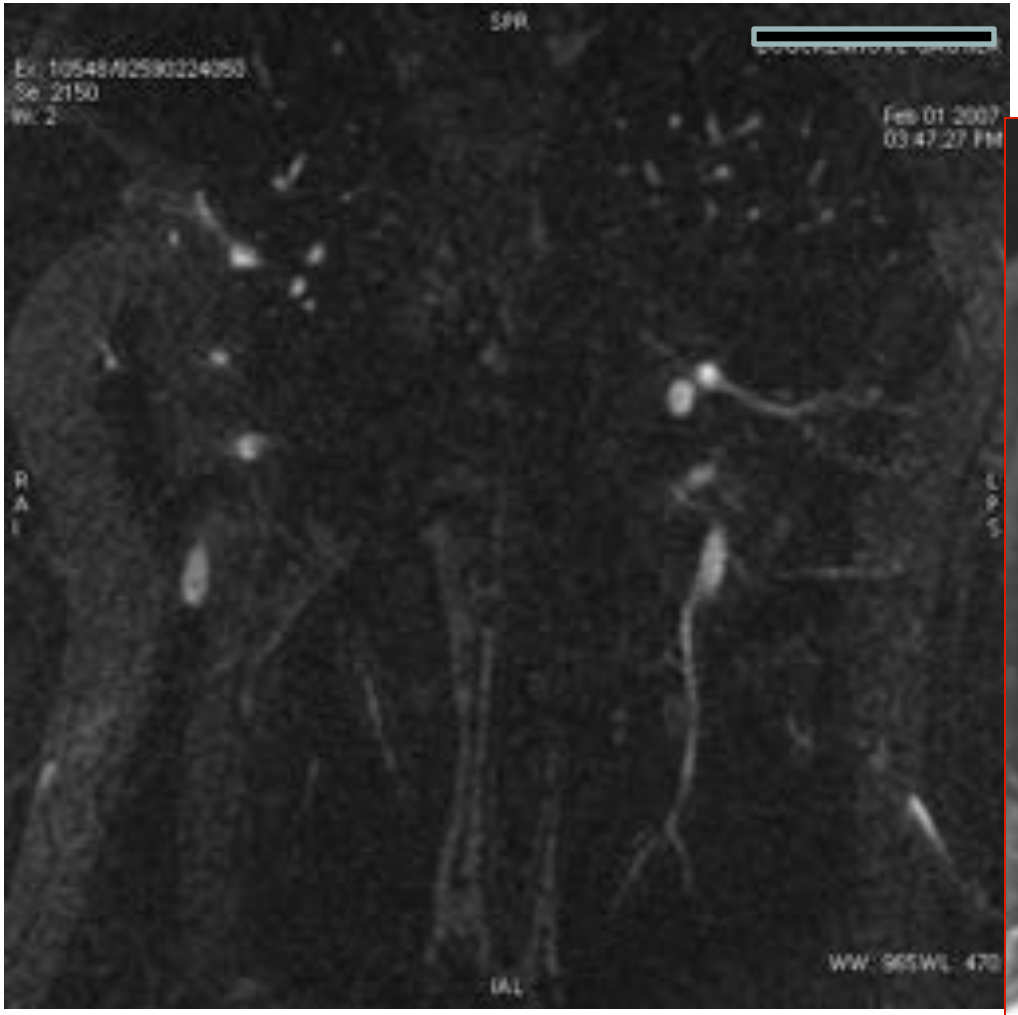

Chenaux atriaux / Mustard

Chenaux atriaux / Senning

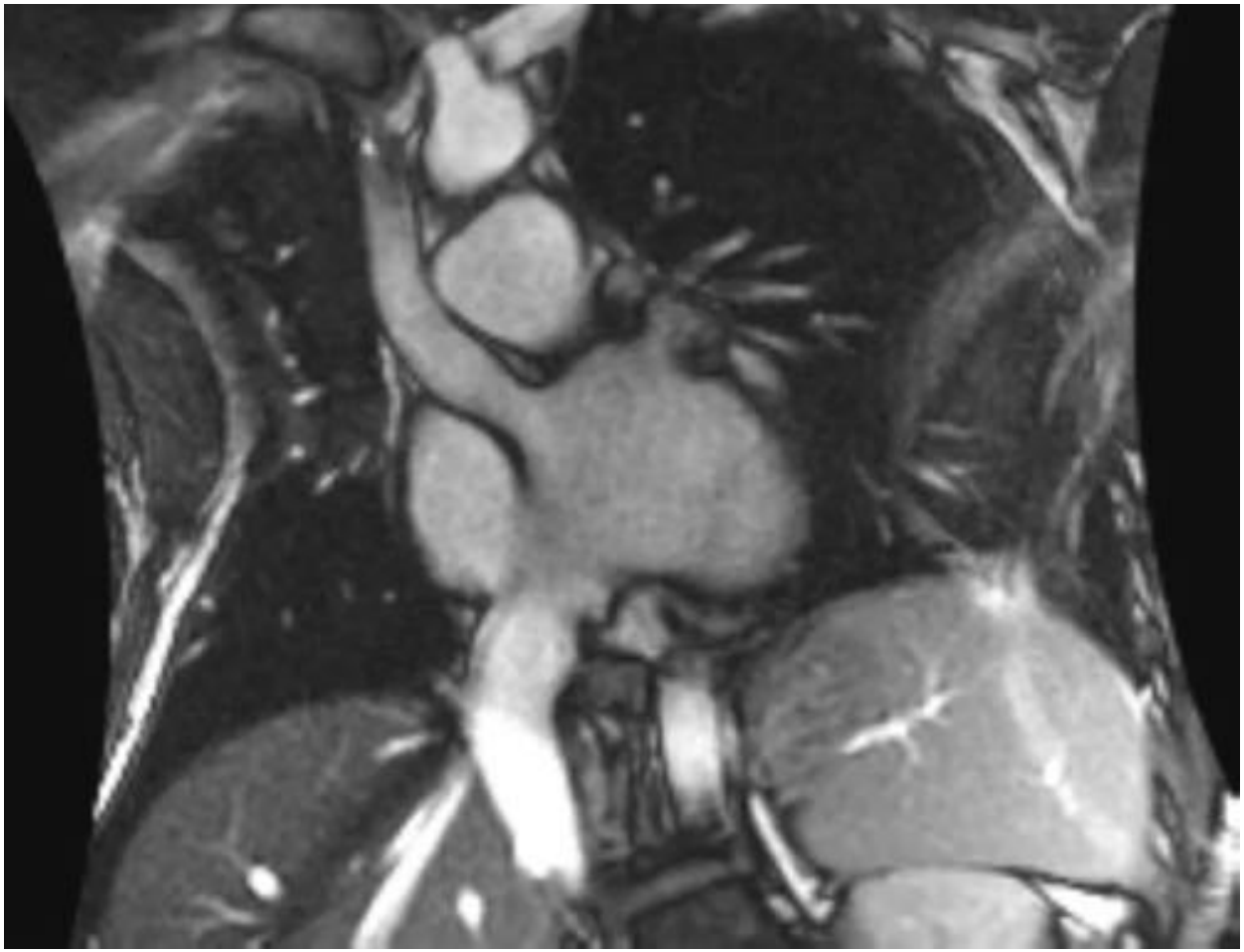

Valves

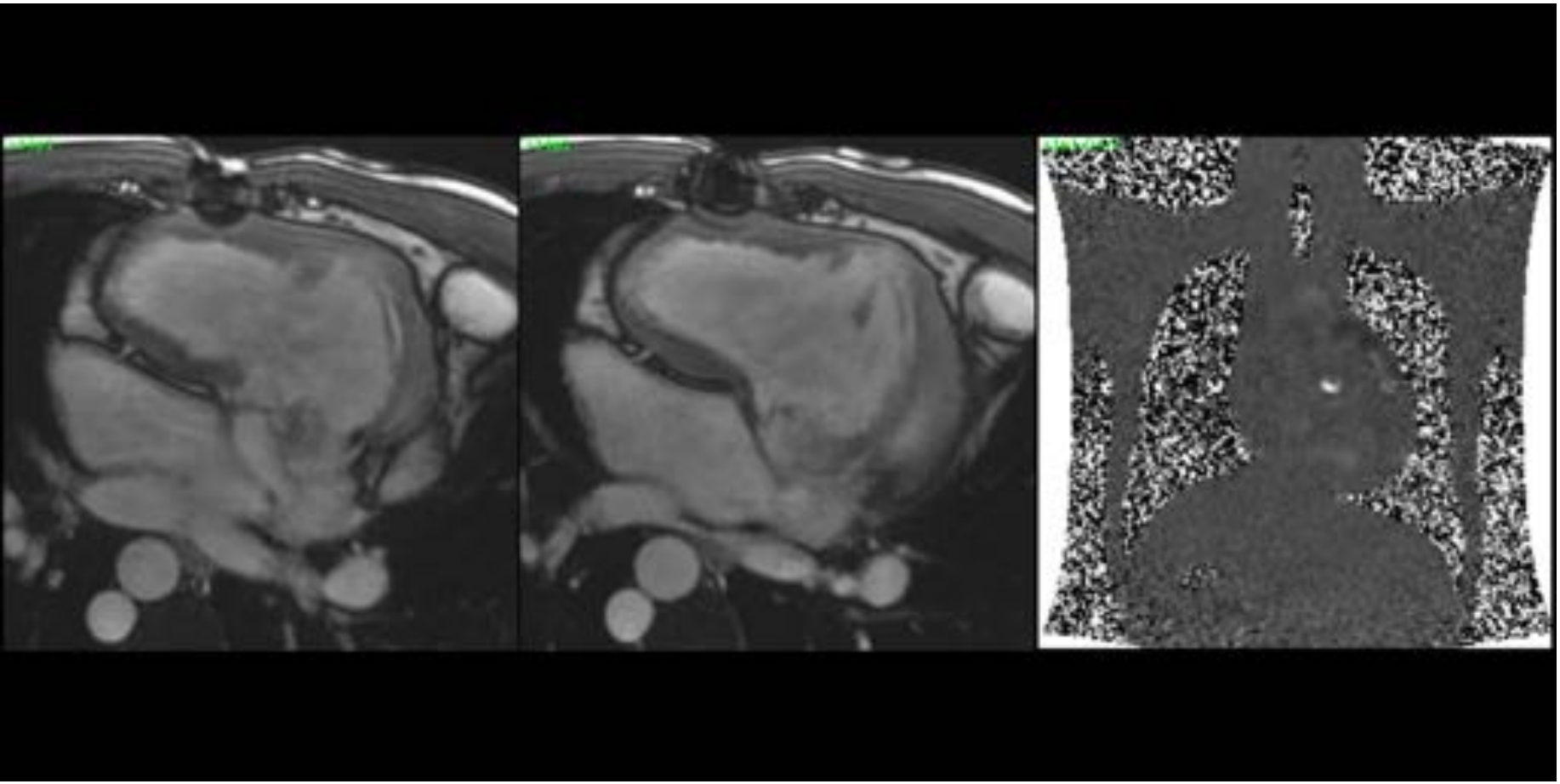

Valves: Velocimetrie

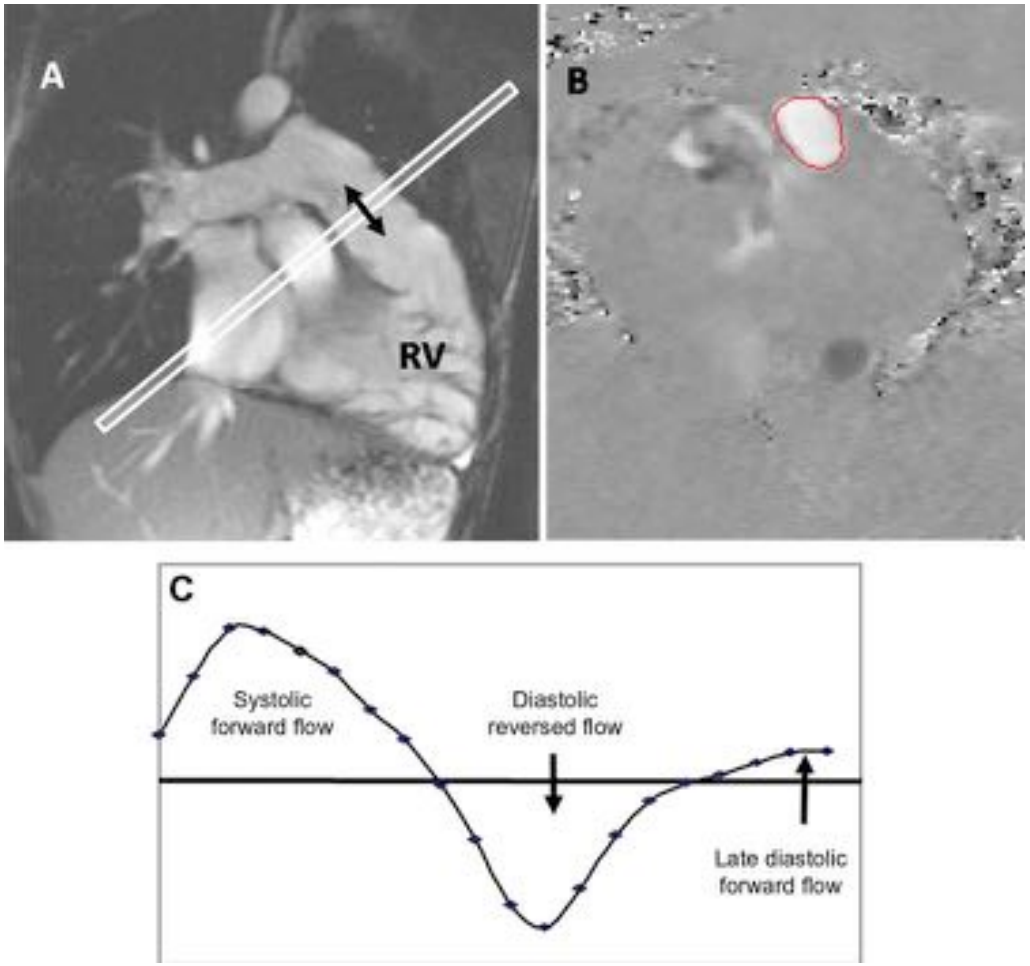

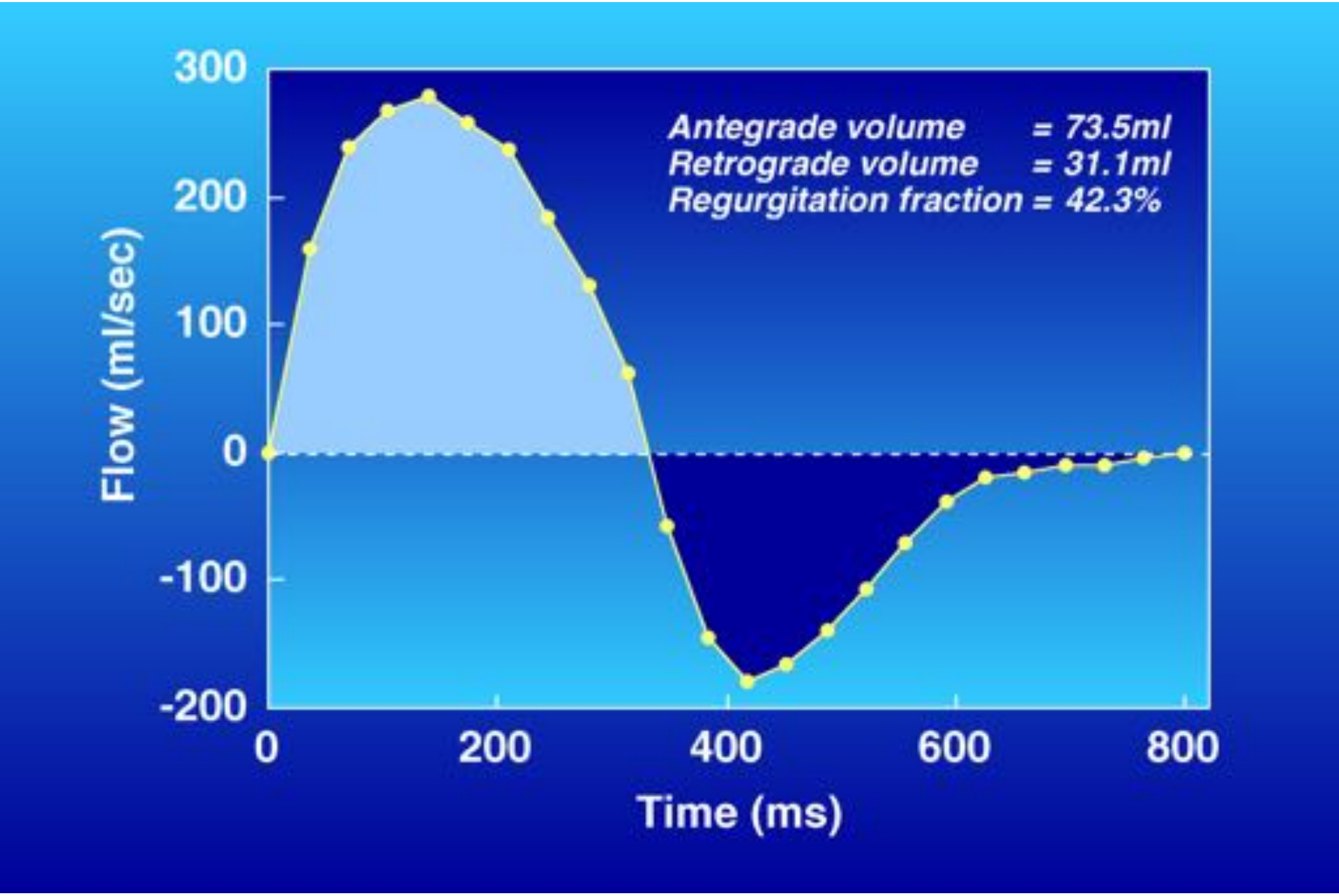
Antegrade volume = 73.5ml
Retrograde volume = 31.1ml
Regurgitation fraction = 42.3%
Flow (ml/sec)
300
200
100
0
-100
-200
0
200
400
600
800
Time (ms)

Fontan

Velocimetrie

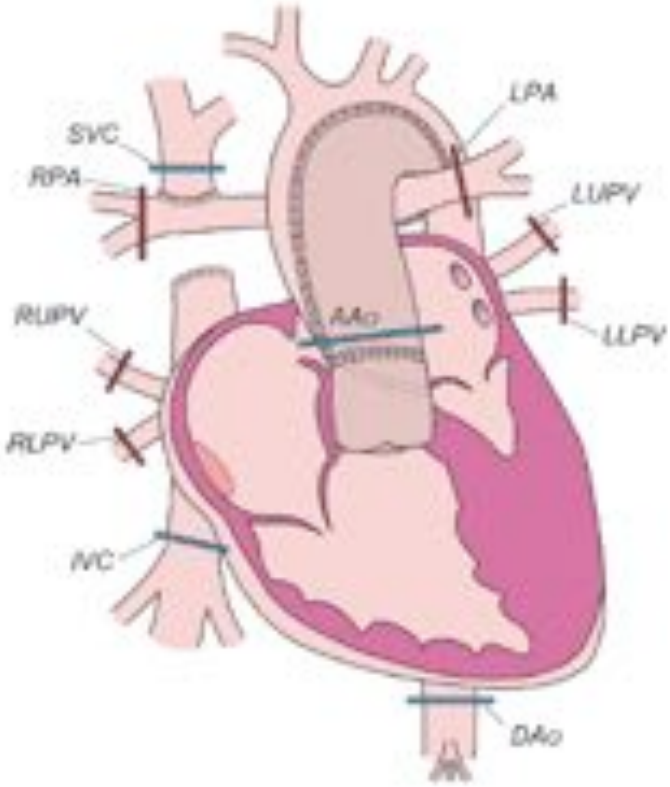

$SPC\ Flow_1 = (RPV_S + LPV_S) - (RPA + LPA)$

$SPC\ Flow_2 = AAo - (SVC + IVC)$

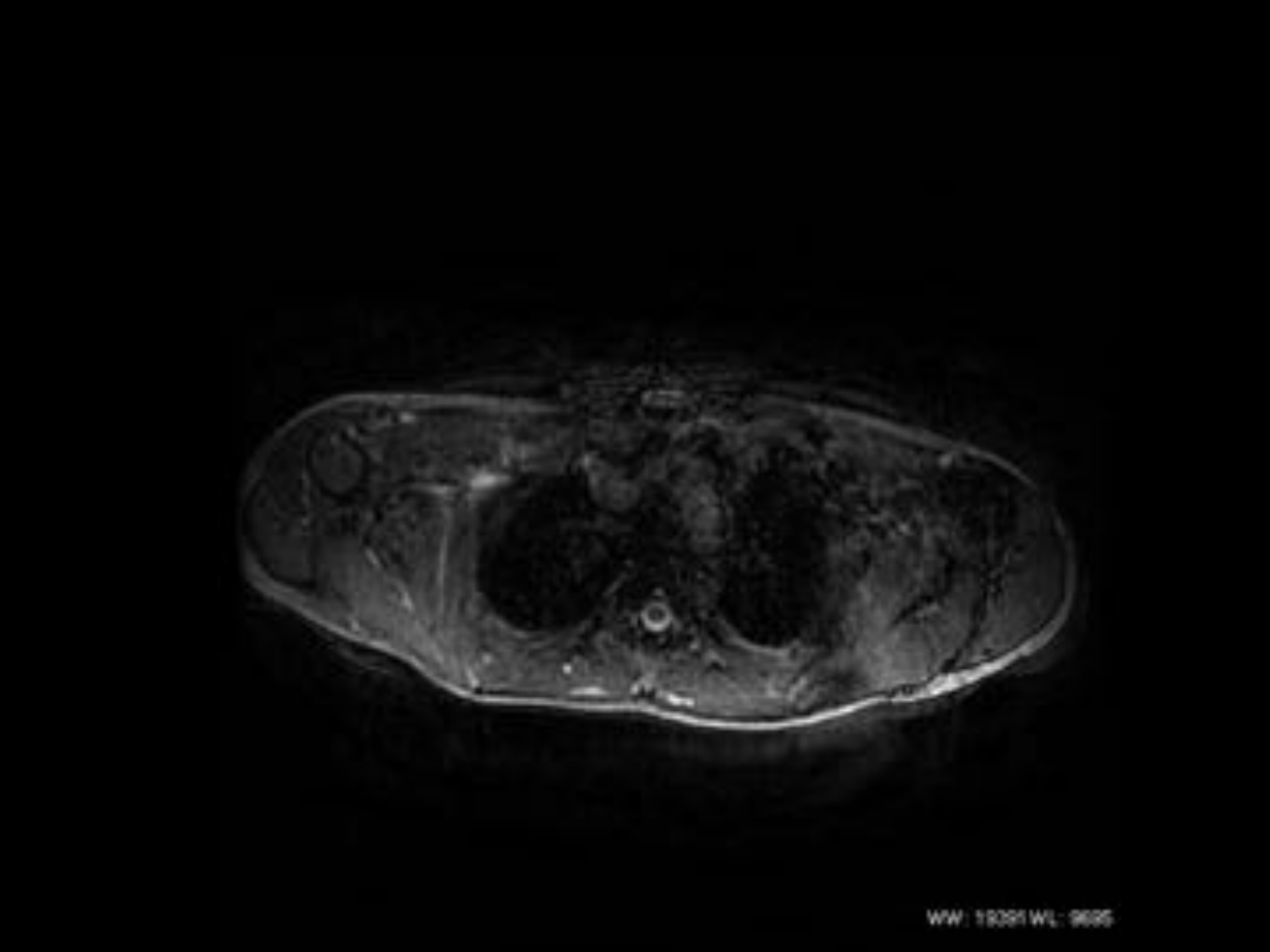
WW: 19391 WL: 9695

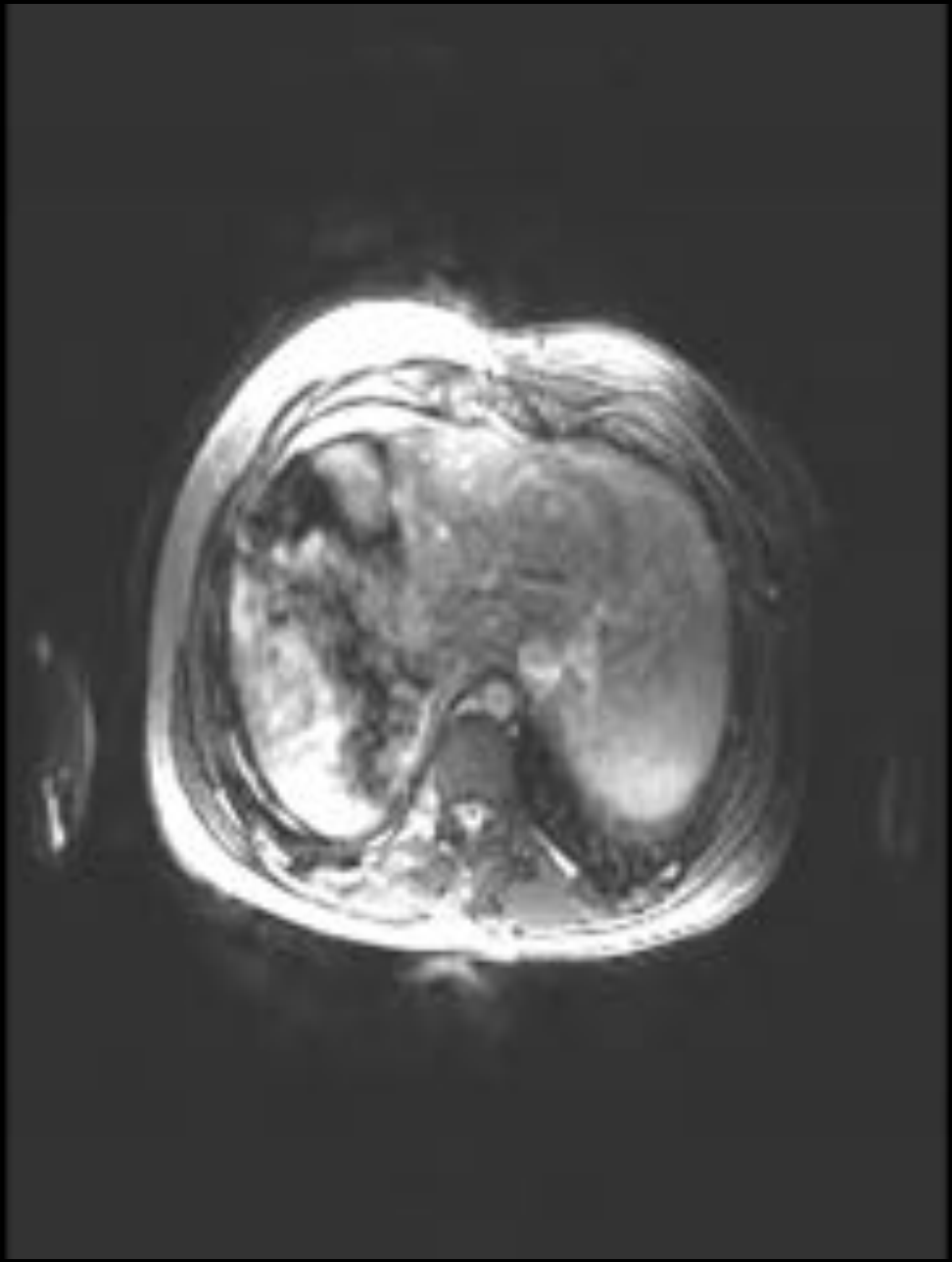

Perfusion myocardique

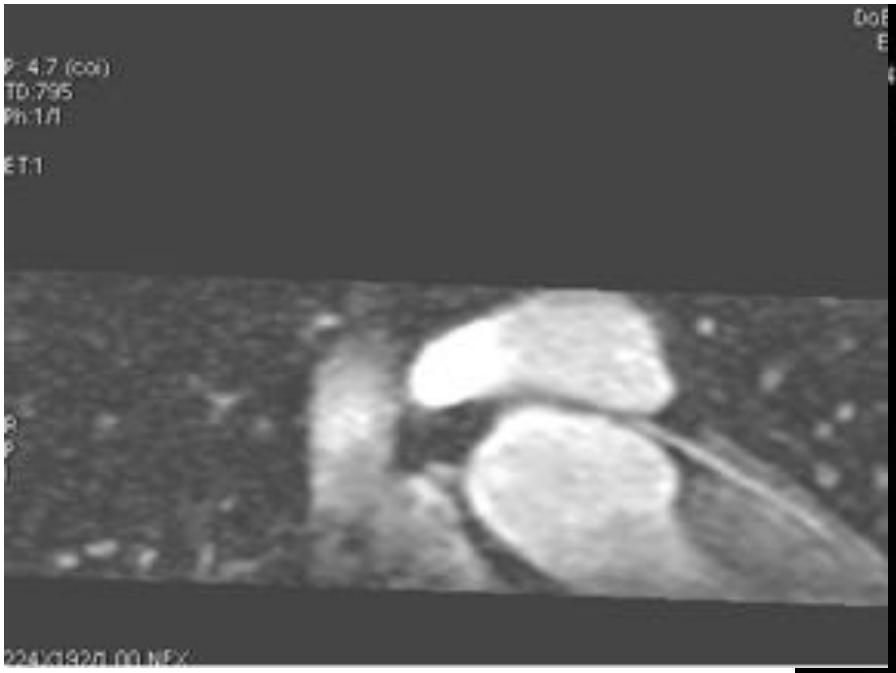

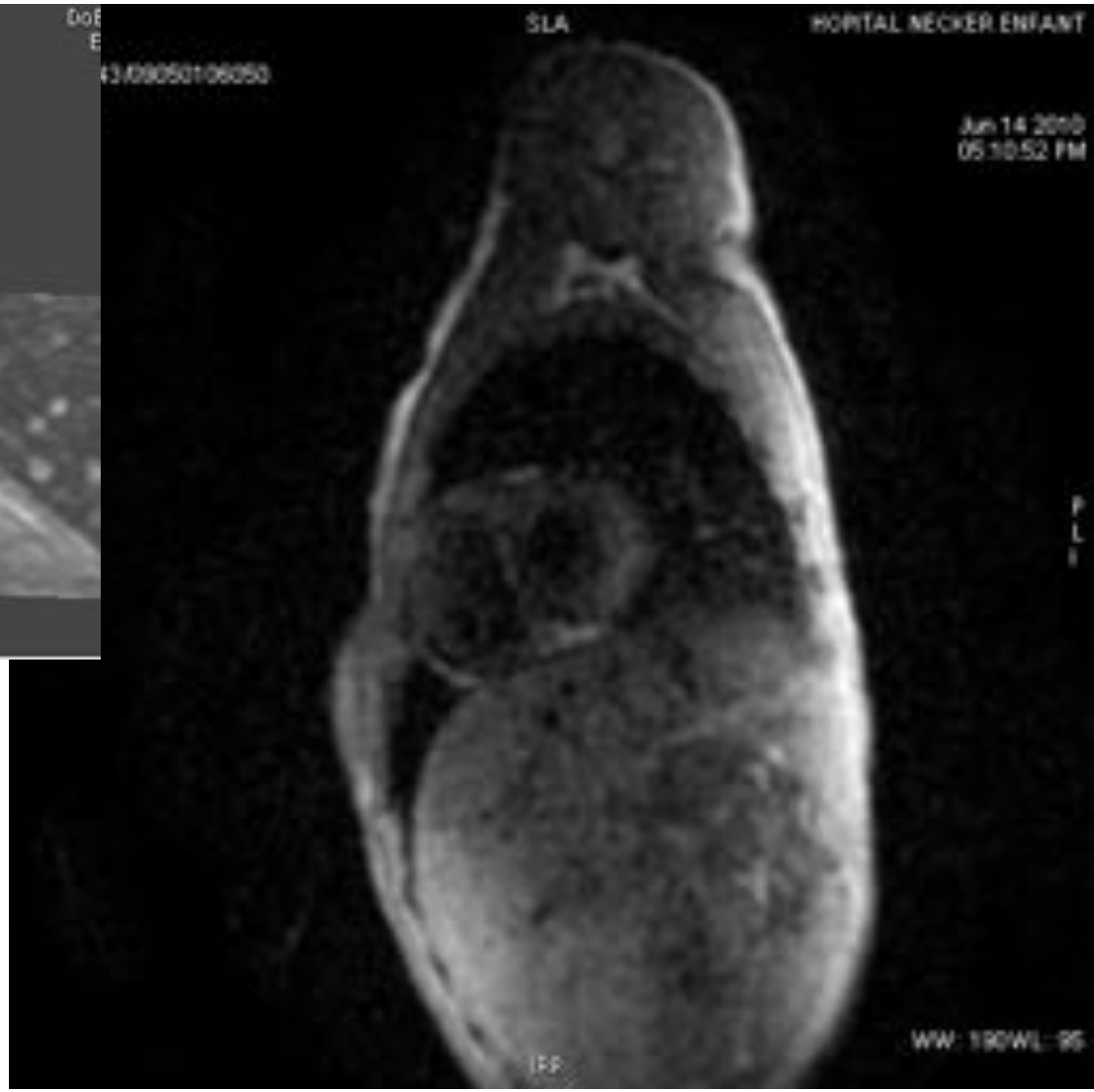

Réserve coronaire

Réserve coronaire

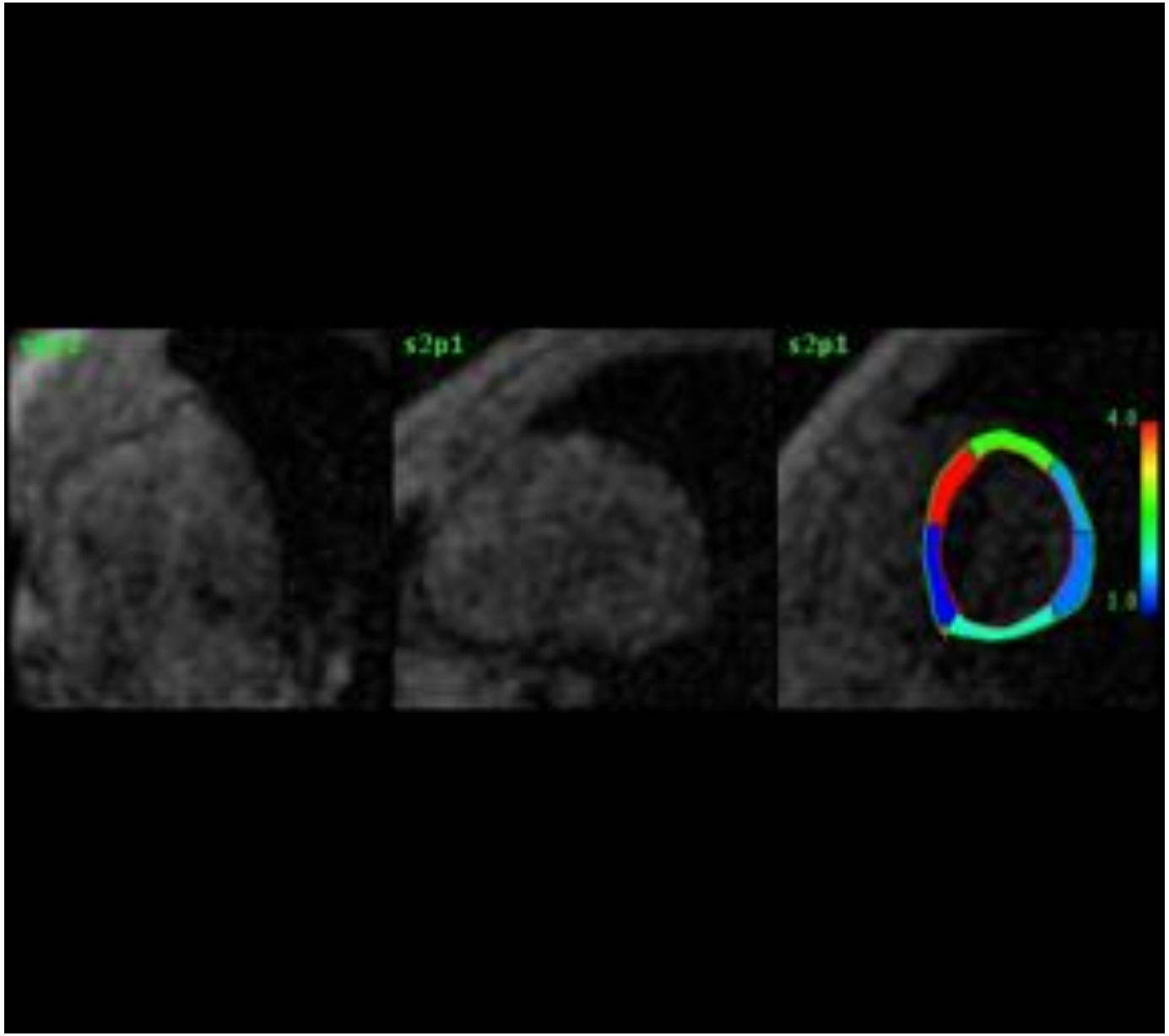

Réserve coronaire

Left Ventricle

Sector Label	Arrival Time (sec)	Peak Time (sec)	Slope (/sec)	Max Slope (/sec)	Signal Intensity Ratio
1	8,8	21,3	16,7	22,4	1,4
2	8,8	21,3	17,5	24,9	1,1
3	8,8	21,3	22,7	26,2	1,5
4	8,8	21,3	17,8	22	0,9
5	8,8	21,3	19,9	23	0,9
6	10,8	21,3	20,6	30,2	0,7

Left Ventricle

Sector Label	Arrival Time (sec)	Peak Time (sec)	Slope (/sec)	Max Slope (/sec)	Signal Intensity Ratio
1	9,2	14,2	24	29,6	0,7
2	11,3	14,2	28,6	27,1	0,7
3	11,3	14,2	29,2	29,8	0,5
4	11,3	14,2	33,1	33	0,5
5	9,2	14,2	38,7	39,8	0,8
6	9,2	14,2	28,9	26,8	0,6

Réserve coronaire

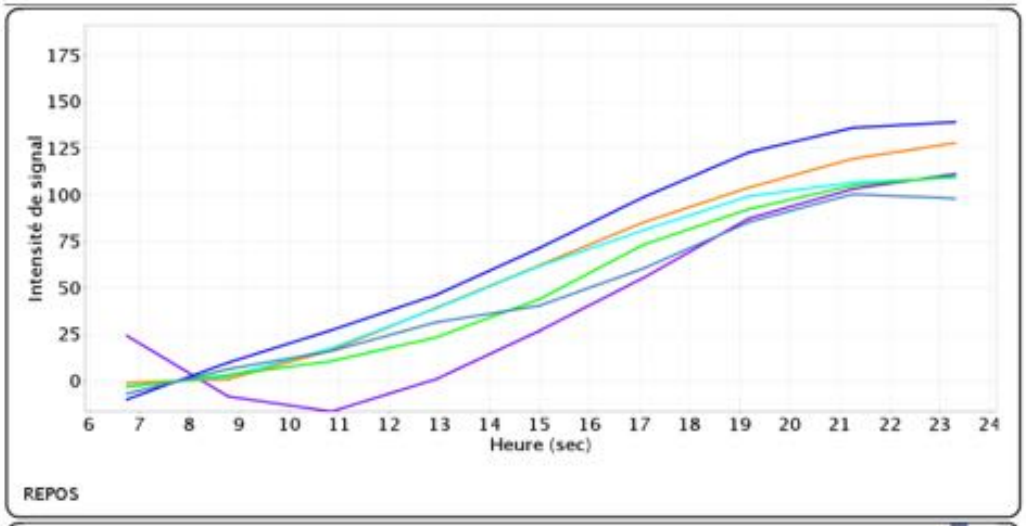

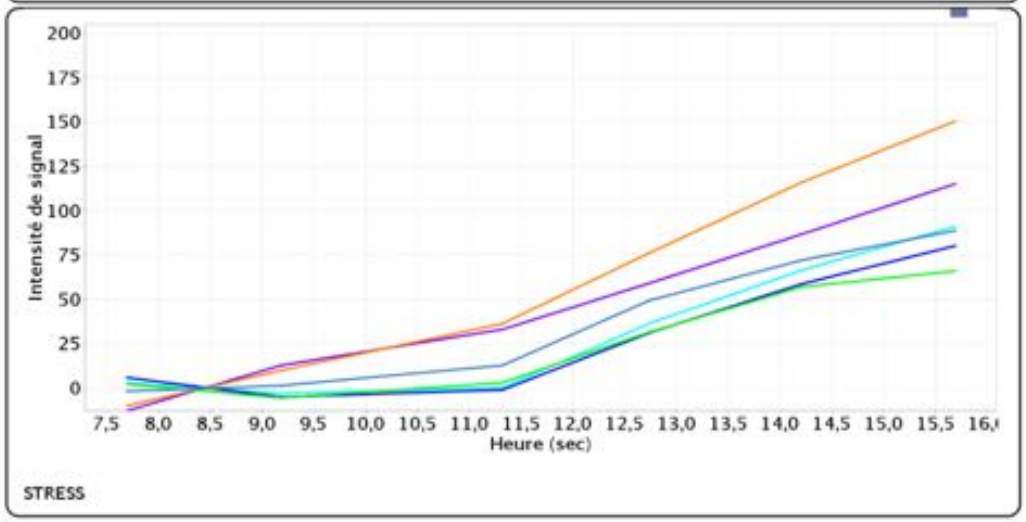

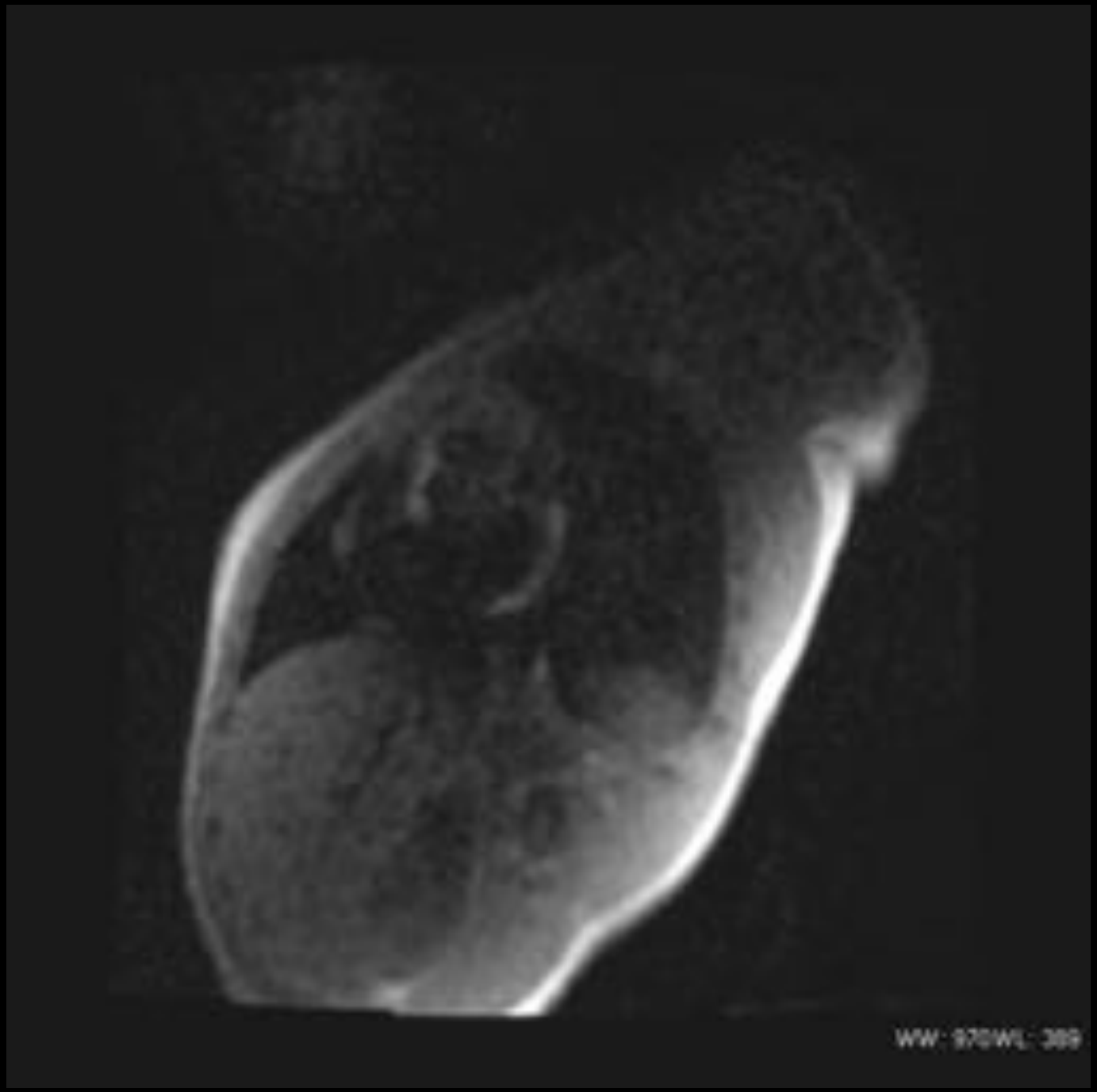
WW: 970 WL: 389

Perfusion pulmonaire

Perfusion pulmonaire

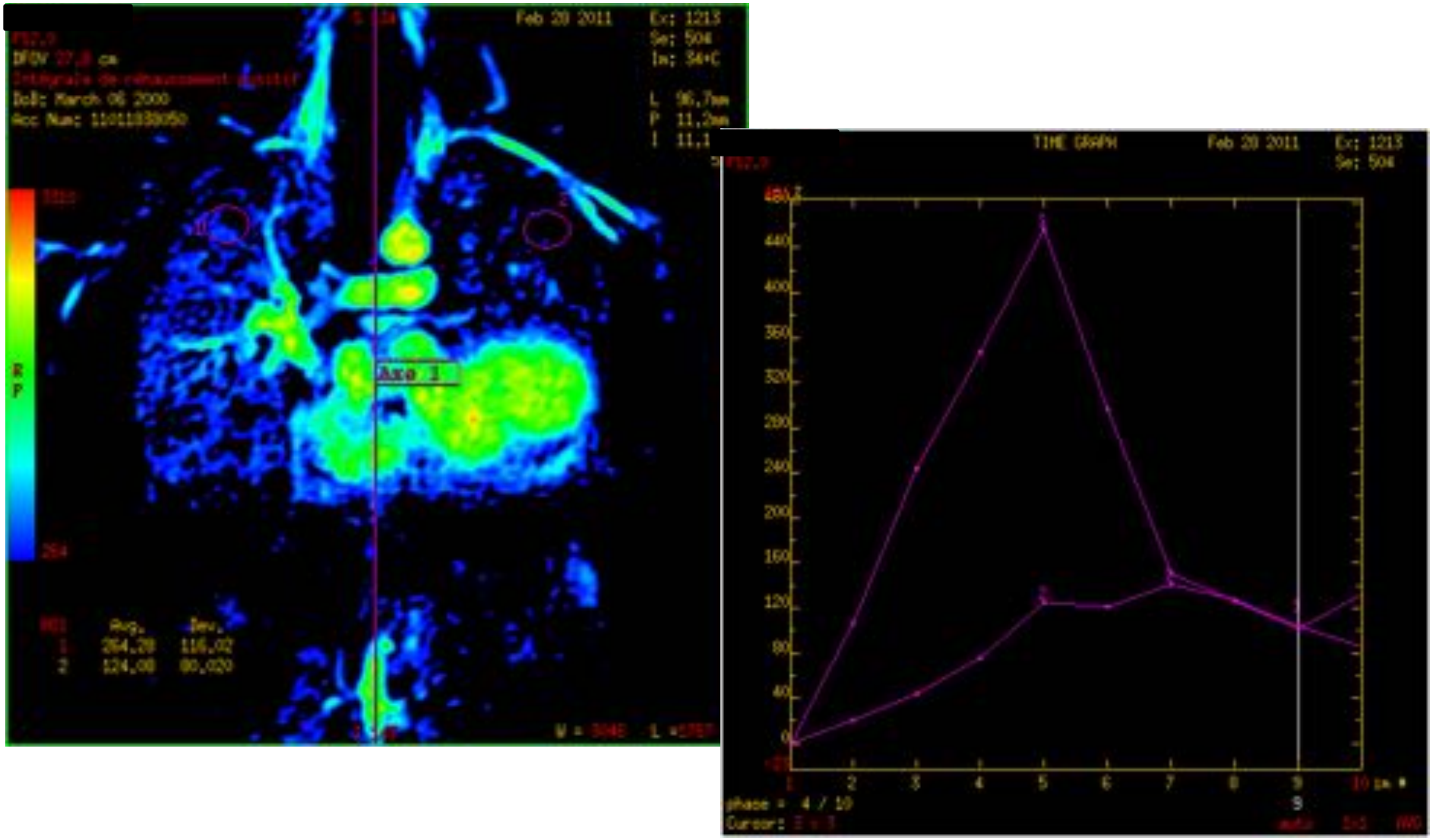

Analyse tissulaire

- *Oedeme*
- *Graisse*
- *Fibrose*
- *Composition tissulaire (spetroscopie)*

Analyse tissulaire

- Pathologies inflammatoire: myocardite aigue, péricardite
- Myocardiopathies: hypertrophique, dilatative, dysplasie arytmogène du ventricule droit
- Recherche de fibrose ventriculaire dans les cardiopathies congenitales (VD systemique, Tetralogie de Fallot, ALCAPA etc)
- Pathologies avec altération de la composition tissulaire (pathologies métaboliques, glycogénose, amyloïdes, Fabry disease)

Analyse tissulaire

- *Edema*
- T2-weighted image sensitivity detects tissue edema with the long
- T2 of water bound protons as the contrast-generating mechanism, resulting in a high signal intensity of edematous tissue.

- *Hyperemia and capillary leak (myocardial early gadolinium enhancement)*
- Contrast-enhanced fast spin-echo T1-weighted MR is used to assess myocardial hyperemia and inflammation.

- *Necrosis and fibrosis (late gadolinium enhancement [LGE])*
- Myocardial LGE reflects irreversible myocardial injury (i.e., necrosis and fibrosis

- *Schultz JS, et al. Mayo Clin Proc. 2009*

Acute myocarditis

Cardiovascular Magnetic Resonance

- Primary tool for non invasive assessment of myocardial inflammation

- *Diagnostic CMR targets*:

1. Functional abnormalities
2. Pericardial effusion
3. Morphological abnormalities
4. Tissue characterization

Myocardite aigue

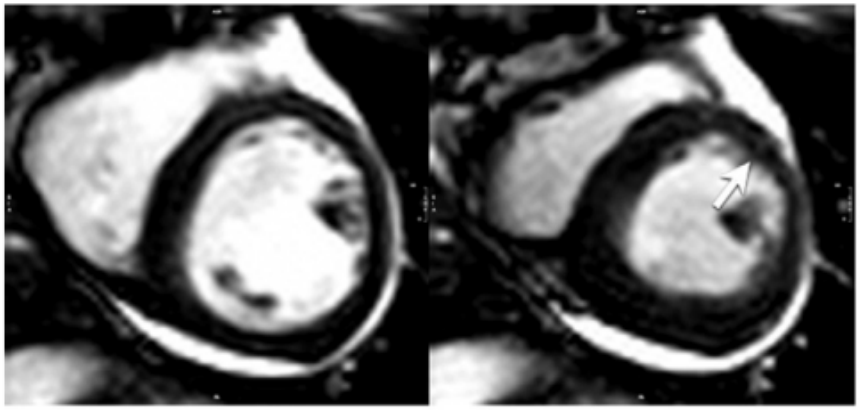

Diastole Systole

Function

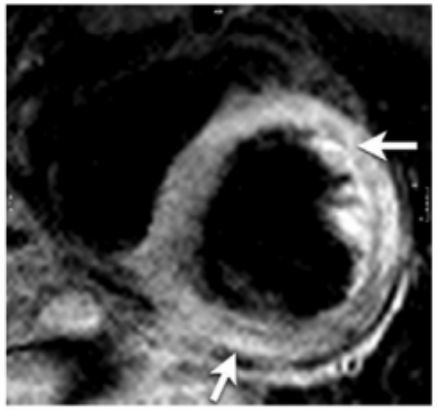

T2-weighted image

Edema

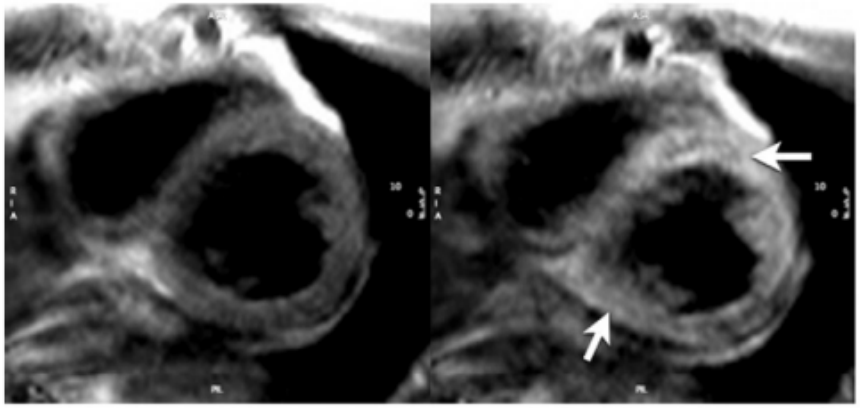

Early enhancement before contrast

Early enhancement after contrast

Hyperemia, capillary leakage

Late enhancement after contrast

Necrosis/scar

CMR in Acute myocarditis

Table 1
Published controlled studies on CMR in myocarditis

	Validation	n *patients*	n *controls*
Friedrich et al., Circulation 1998 (9)	Clinical	19	18
Laissy et al., Chest 2002 (11)	Clinical	20	7
Rieker et al., RoFo 2002 (36)	Clinical	11	10
Laissy et al., Radiology 2005 (37)*	Clinical	24	31
Abdel-Aty et al., J Am Coll Cardiol 2005 (13)	Clinical	25	22
Mahrholdt et al., Circulation 2006 (40)	Histology	87	26
Gutberlet et al., Radiology 2008 (34)**	Histology	48	35
Yilmaz et al., Heart 2008 (43) **	Histology	55	30
		289	**179**

* Comparison to patients with acute myocardial infarction.
** Comparison to patients with clinical evidence, but lack of immunohistologic evidence for chronic myocarditis

Myocardite aigue

Table 9

Overview of the Diagnostic Accuracy of Individual Tissue Criteria as Assessed in Controlled Trials

	Validation	Sensitivity (%)	Specificity (%)	Accuracy (%)	PPV (%)	NPV (%)
Early myocardial gadolinium enhancement						
Friedrich et al., *Circulation* 1998 (9)	Clinical	84	89	86	89	84
Laissy et al., *Chest* 2002 (11)	Clinical	85	100	89	100	70
Abdel-Aty et al., *J Am Coll Cardiol* 2005 (13)	Clinical	80	68	74	74	78
Gelbenet et al., *Radiology* 2008 (34)	Histology	63	86	72	86	63
Pooled data (n = 184)		74	83	78	88	70
T2						
Reiser et al., *Rofo* 2002 (36)	Clinical	100	50	76	69	100
Laissy et al., *Chest* 2002 (11)	Clinical	45	100	59	100	39
Abdel-Aty et al., *J Am Coll Cardiol* 2005 (13)	Clinical	84	74	79	78	81
Gelbenet et al., *Radiology* 2008 (34)	Histology	67	69	67	74	60
Pooled data (n = 178)		70	71	70	77	63
Late enhancement						
Reiser et al., *Rofo* 2002 (36)	Clinical	45	60	52	56	50
Abdel-Aty et al., *J Am Coll Cardiol* 2005 (18)	Clinical	84	100	71	78	62
Mahrholdt et al., *Circulation* 2006 (40)	Histology	95	96	96	99	91
Gelbenet et al., *Radiology* 2008 (34)	Histology	27	80	49	65	44
Yilmaz et al., *Heart* 2008 (45)	Histology	35	83	51	81	39
Pooled data (n = 336)		59	86	69	89	53

Abbreviations as in Table 2.

CMR in Acute myocarditis

Table 4

Overview of the Diagnostic Accuracy of Several Combinations of Tissue Criteria

	Validation	Sensitivity (%)	Specificity (%)	Accuracy (%)	PPV (%)	NPV (%)
T2 + LGE						
Abdel-Aty et al., *J Am Coll Cardiol* 2005 (13)	Clinical	40	100	69	100	61
Gutberlet et al., *Radiology* 2008 (34)	Histology	17	91	48	73	44
Pooled data (n = 130)		25	95	56	86	50
T2 and/or LGE						
Abdel-Aty et al., *J Am Coll Cardiol* 2005 (13)	Clinical	88	74	81	100	85
Gutberlet et al., *Radiology* 2008 (34)	Histology	50	57	52	80	25
Pooled data (n = 130)		60	66	62	79	43
Any 1 of 3						
Abdel-Aty et al., *J Am Coll Cardiol* 2005 (13)	Clinical	100	46	75	58	100
Gutberlet et al., *Radiology* 2008 (42)	Histology	81	69	67	68	65
Pooled data (n = 130)		88	68	70	68	76
Any 2 of 3						
Abdel-Aty et al., *J Am Coll Cardiol* 2005 (13)	Clinical	76	96	85	95	79
Gutberlet et al., *Radiology* 2008 (34)	Histology	63	89	73	88	63
Pooled data (n = 130)		67	91	78	91	69

LGE = late gadolinium enhancement; other abbreviations as in Table 2.

T2
WW: 2000/WL: 1000

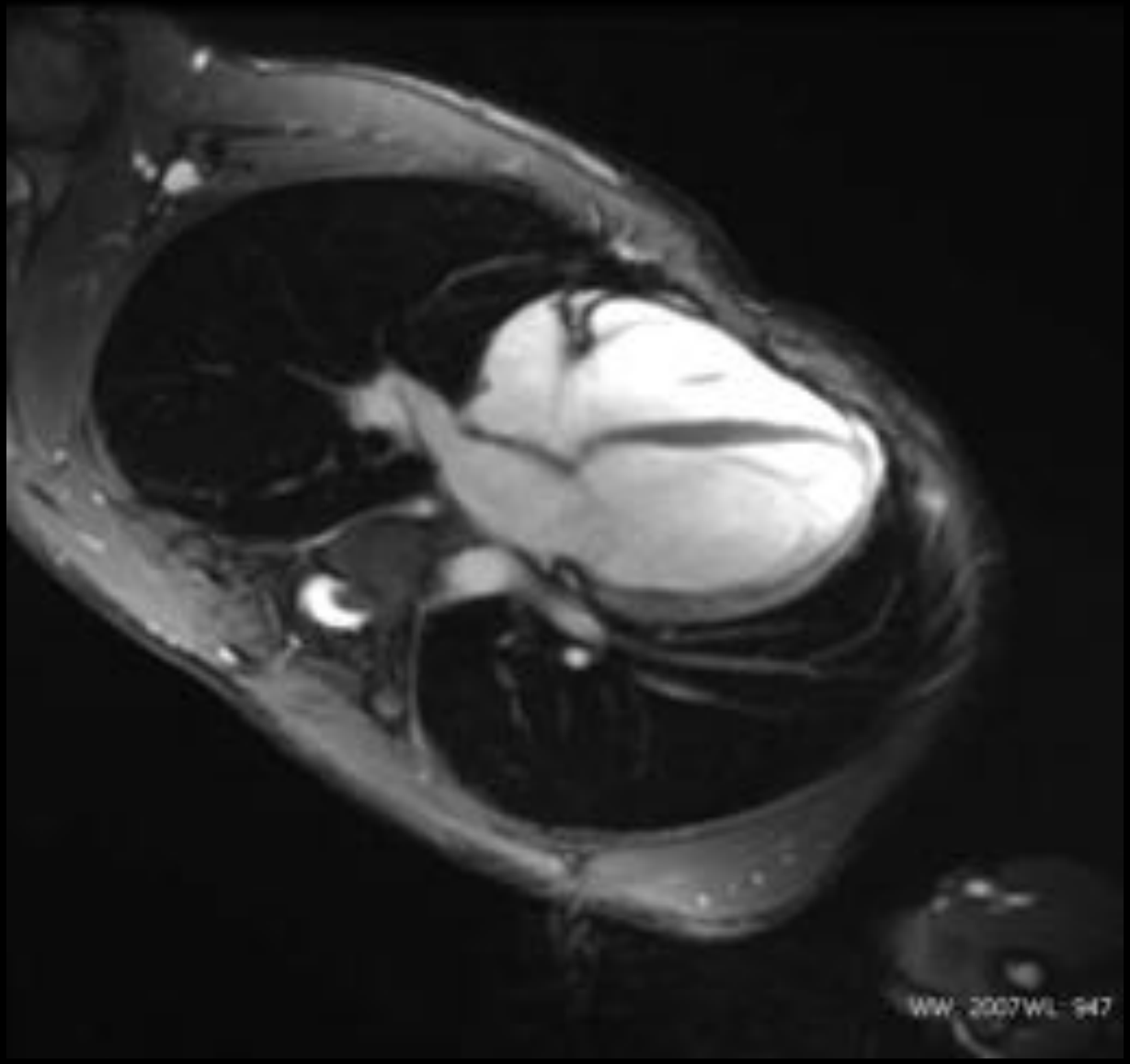
WW: 2007 WL: 947

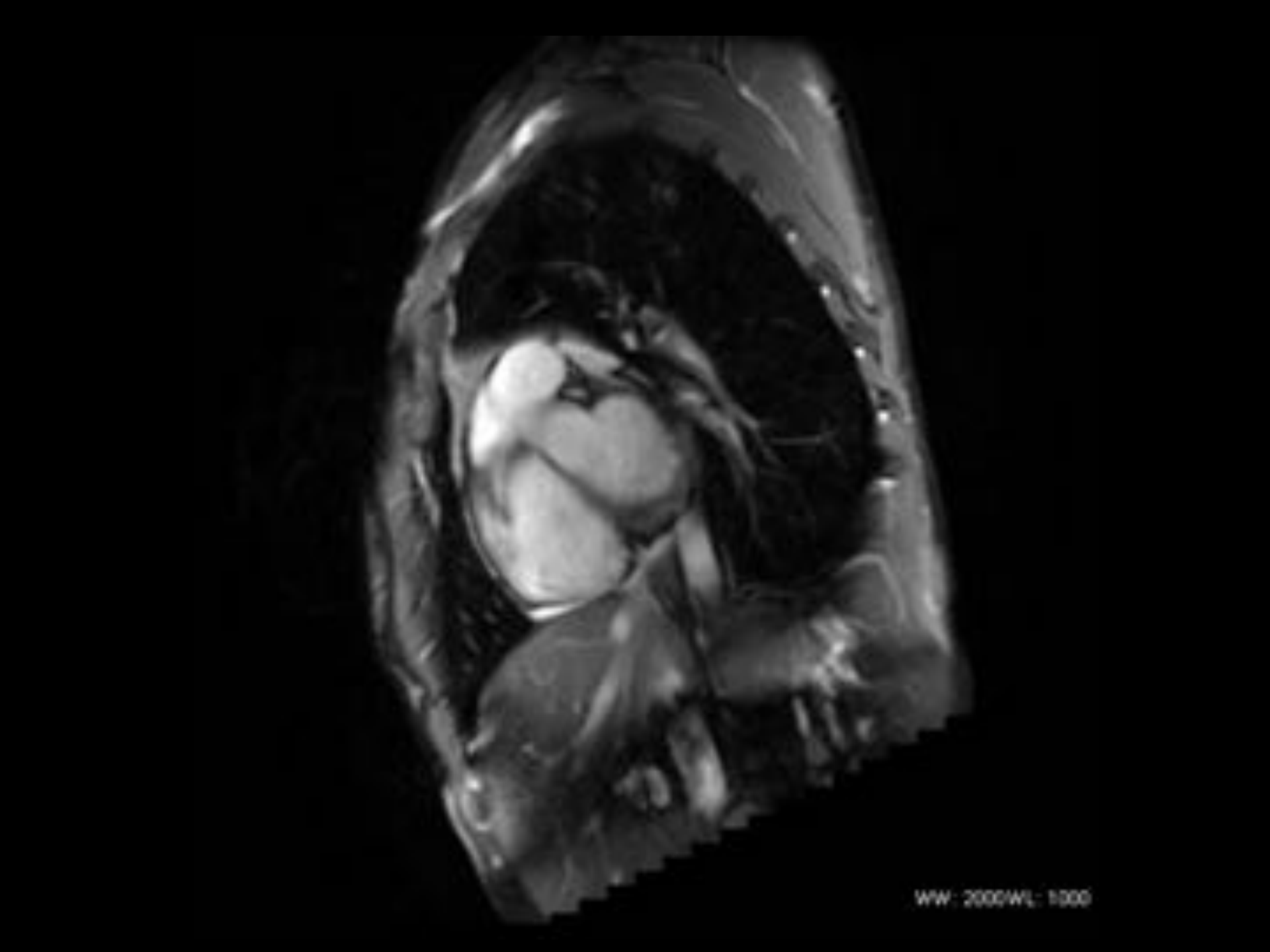
WW: 2000/WL: 1300

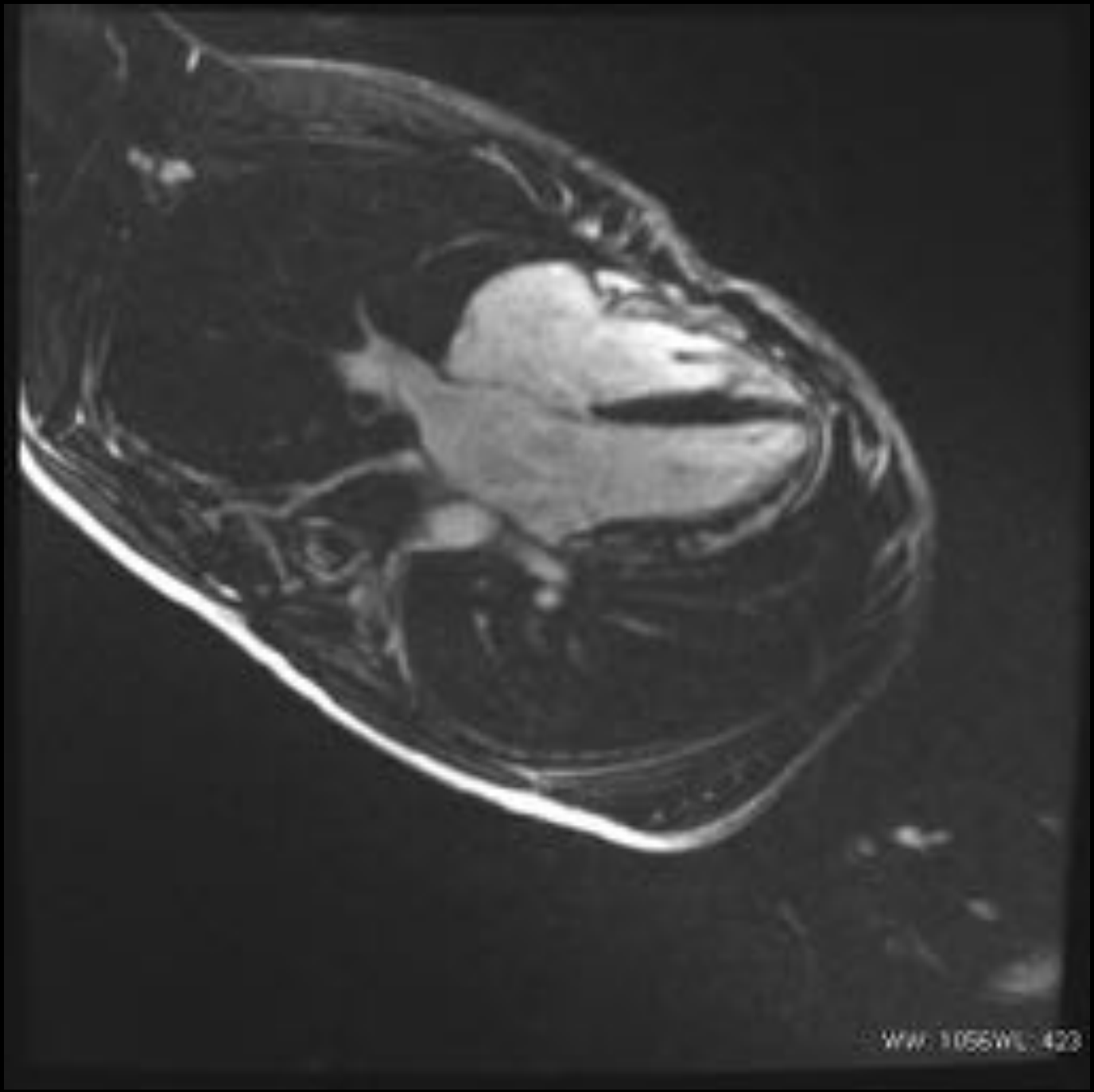
WW: 1056WL: 423

WW: 1006WL: 407

Myocardite aigue

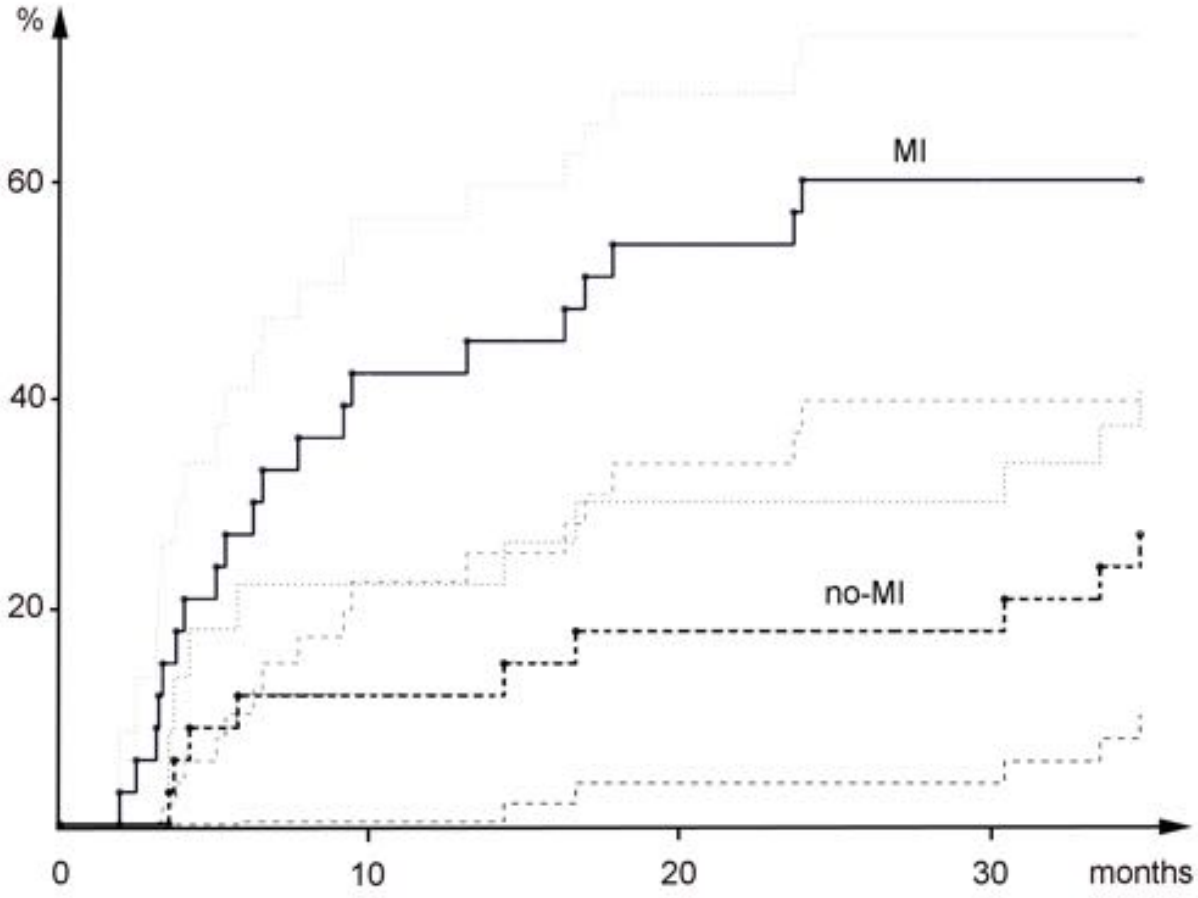

Fibrose VD systémique

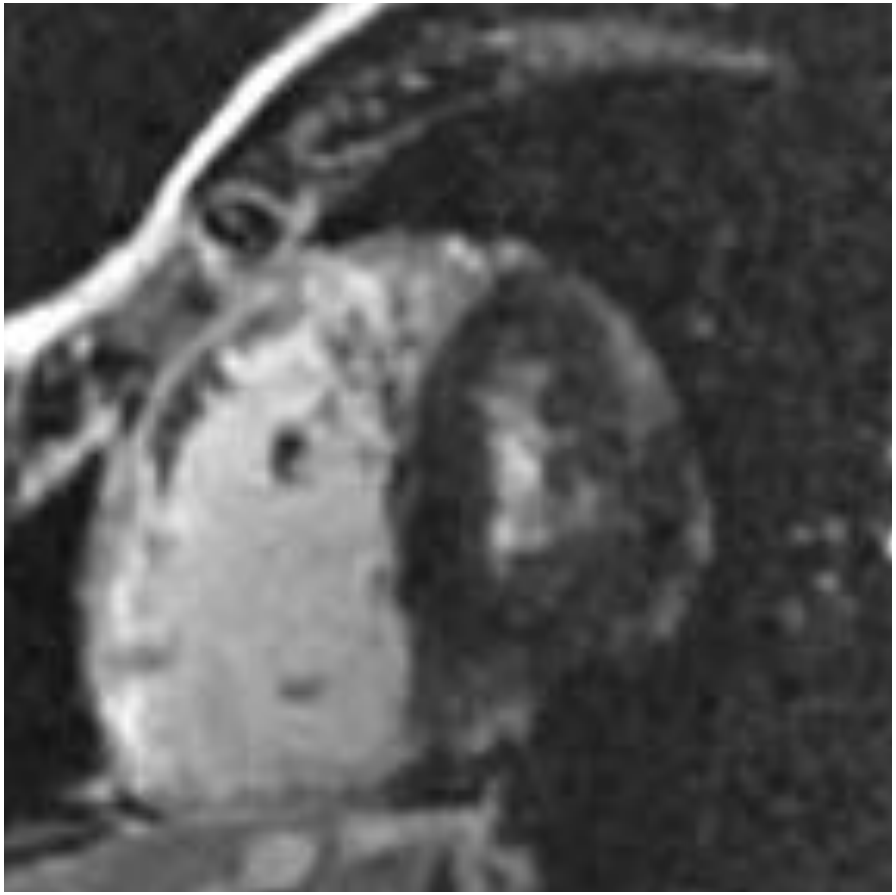

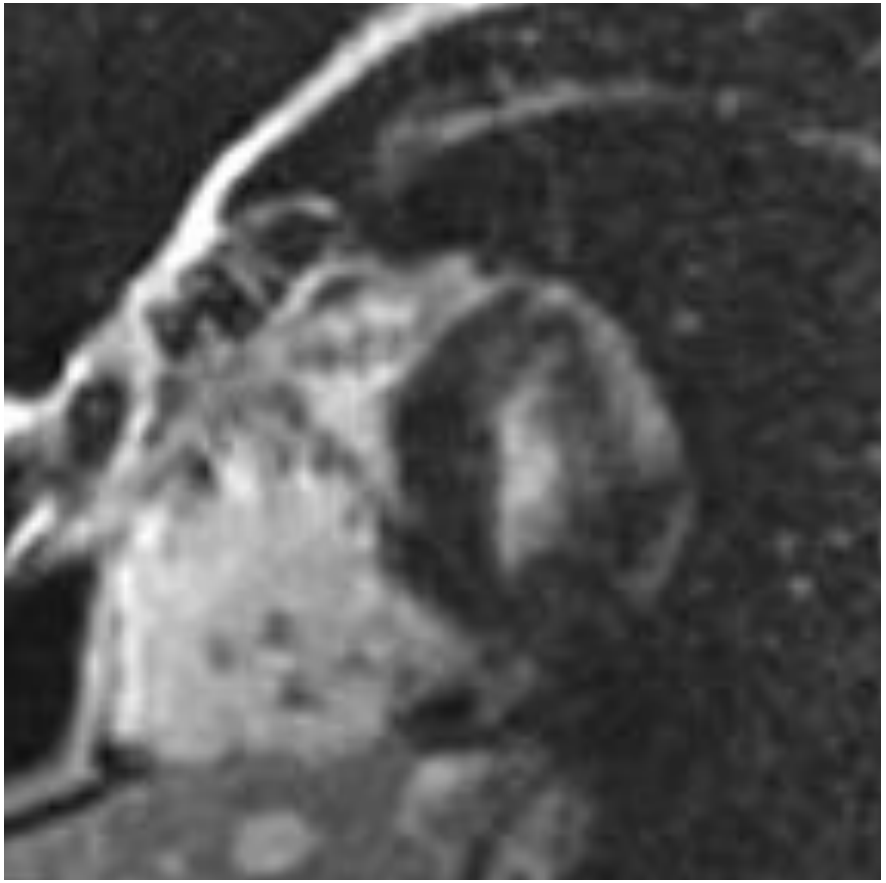

Cardiomyopathie hypertrophique

Morphologie

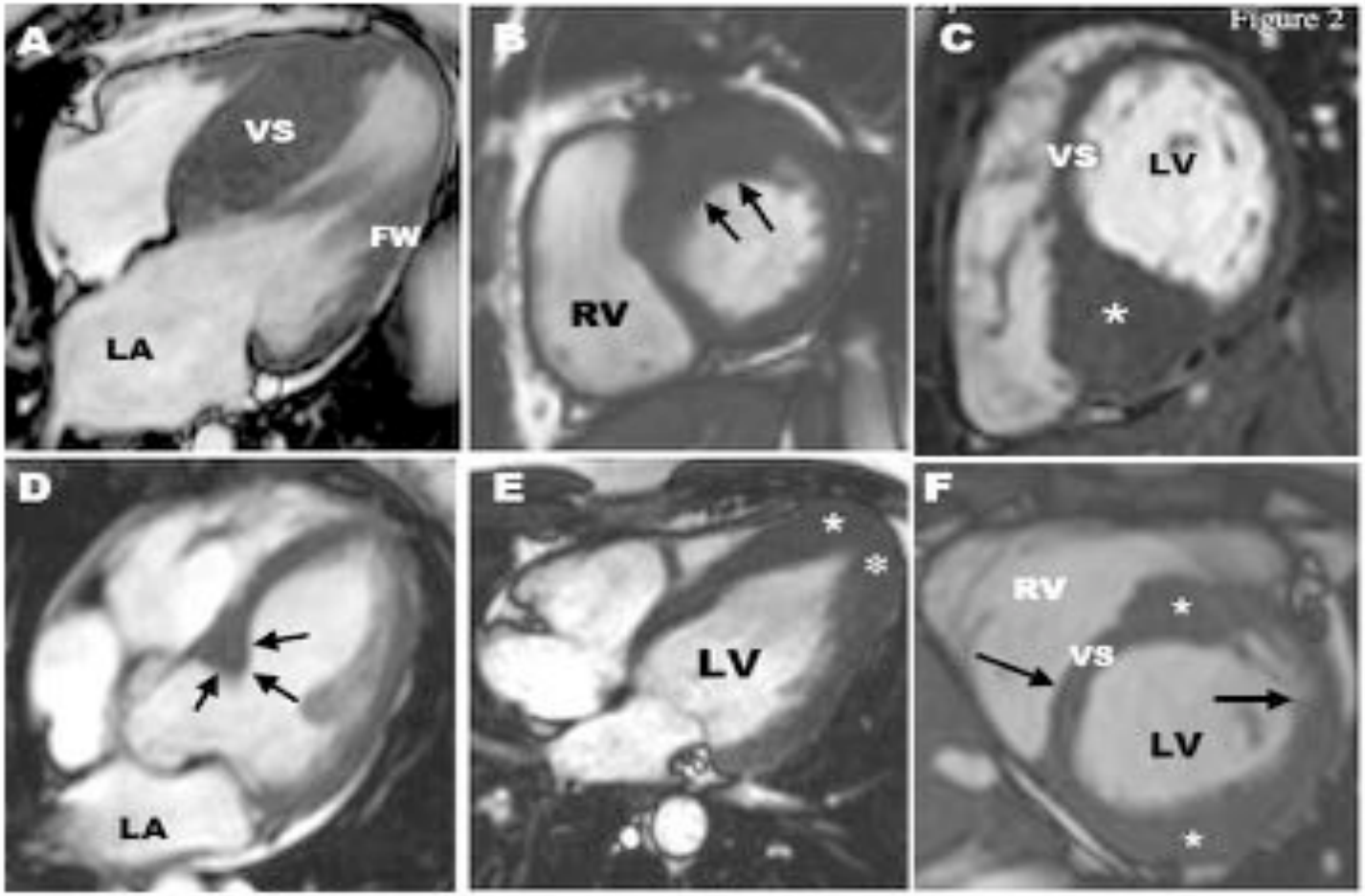

Figure 2 CMR end-diastolic images demonstrating diverse patterns of LVH in HCM. (A) involving ventricular septum (VS), but sparing the LV free wall (FW); **(B)** hypertrophy of the basal anterior free wall and a portion of the contiguous anterior septum, representing the most common area of LV wall thickening in HCM; **(C)** massive hypertrophy (wall thickness, 33 mm) limited to basal posterior ventricular septum (asterisk); **(D)** focal area sharply confined to basal anterior septum (arrows); **(E)** localized to LV apex (asterisks); **(F)** segmental LV hypertrophy of the basal anterior septum and anterolateral wall (asterisks), separated by regions of normal LV thickness (arrows). Adapted with permission, from Maron MS et al[29] FW = free wall; LA = left atrium; LV = left ventricle; RA = right atrium; RV = right ventricle; VS = ventricular septum.

Echo-IRM

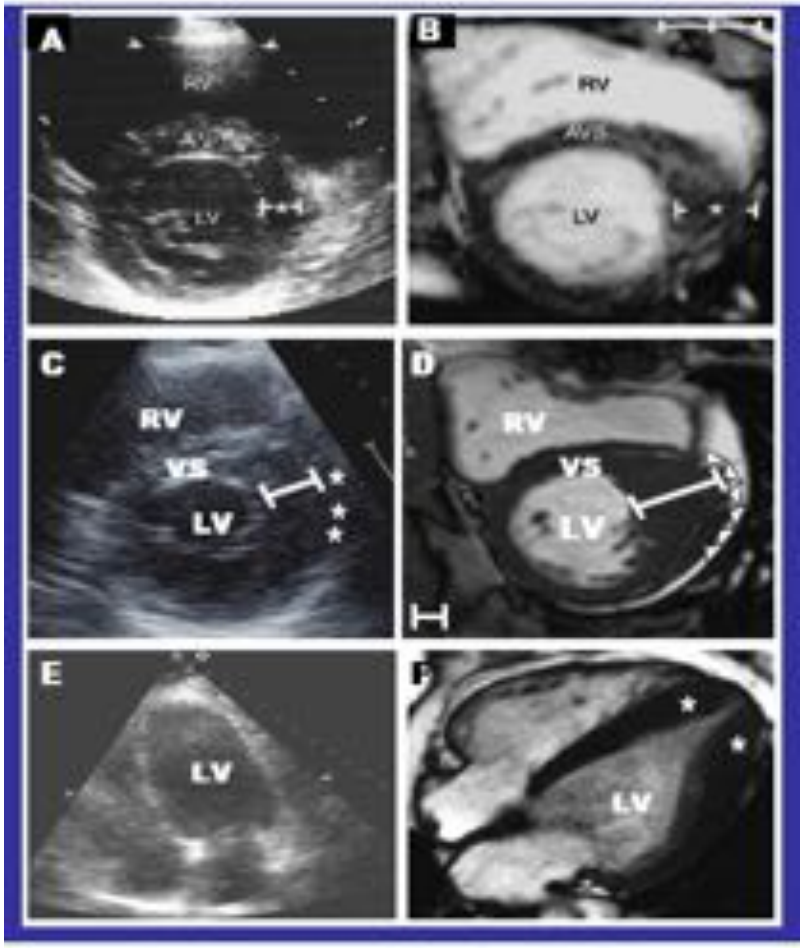

Phenotype

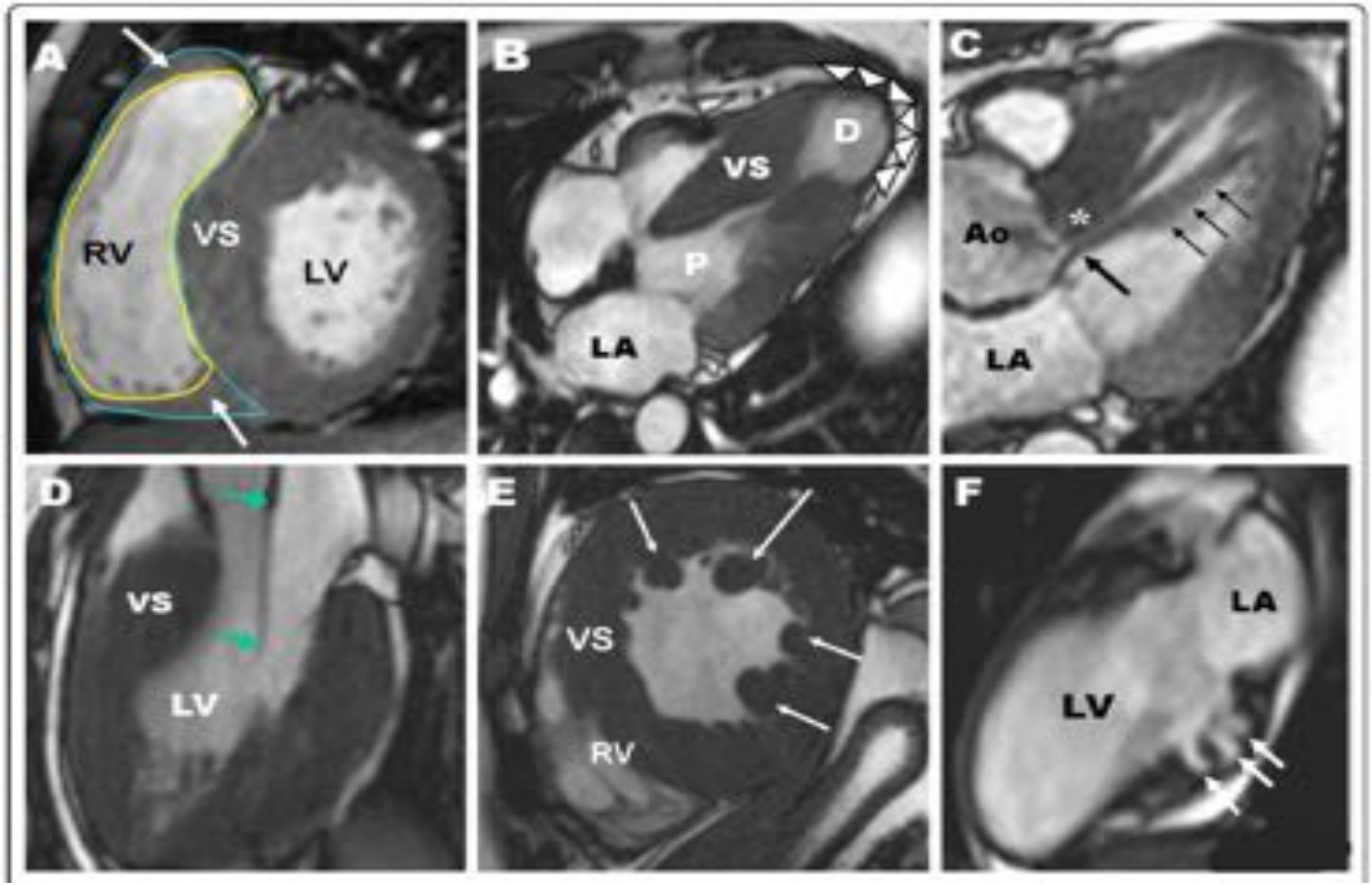

Fibrose

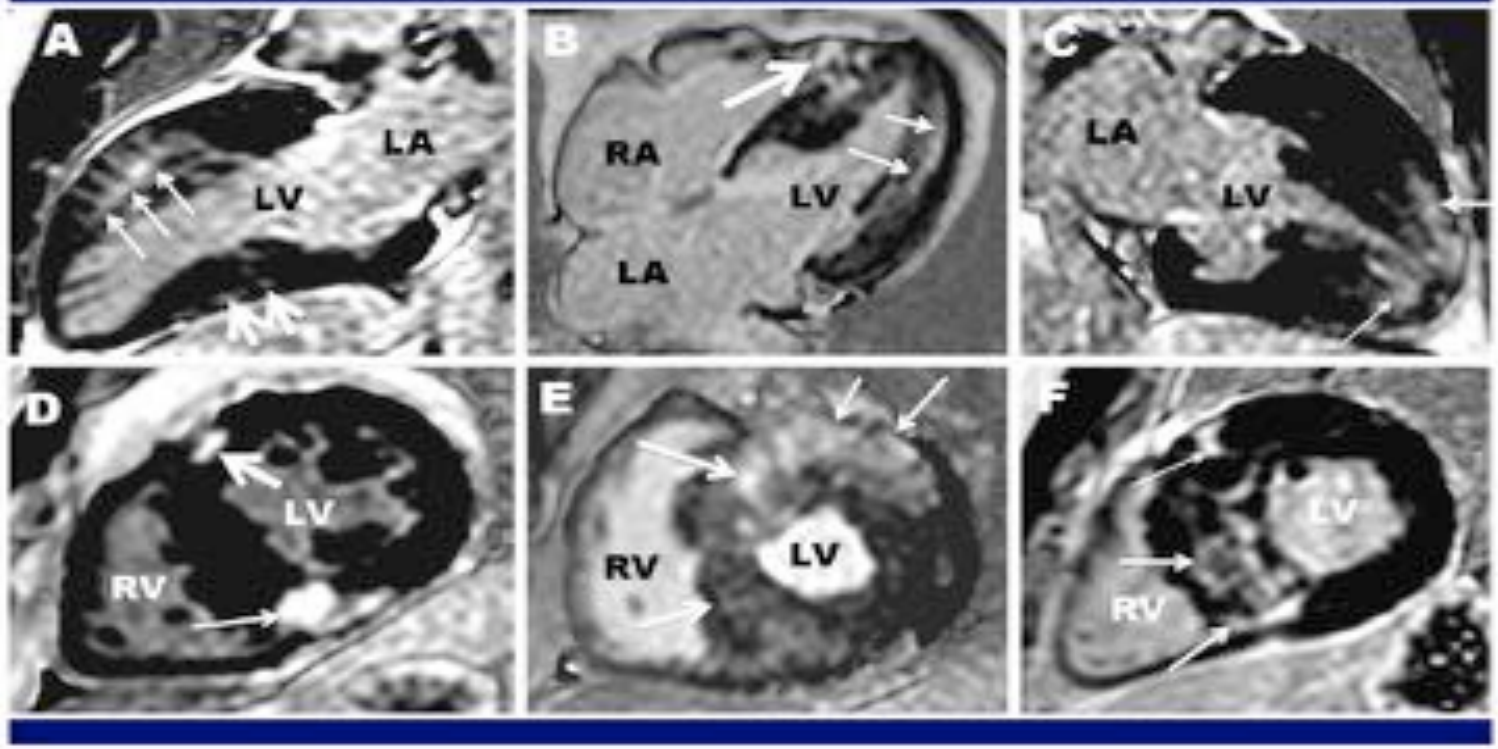

Figure 6 Contrast-enhanced CMR images in 6 different HCM patients demonstrating the diverse pattern and extent of late gadolinium enhancement in this disease (**A**) extensive transmural LGE in the anterior wall (small arrows) with smaller focal area in the inferior wall (small arrows); (**B**) mid-myocardial LGE in the lateral wall (small arrows) and diffuse LGE in the ventricular septum which extends into the RV wall (large arrows) in a 26 year-old man with "end-stage" phase of HCM with an ejection fraction of 40%; (**C**) LGE confined to the LV apex (arrows); (**D**) LGE localized to the insertion area of the RV wall into the anterior (large arrow) and posterior ventricular septum (small arrow); (**E**) transmural LGE involving the majority of the ventricular septum (large arrow) and lateral wall (small arrow); (**F**) Basal short-axis image with transmural LGE located predominantly in the ventricular septum (arrows). RA = right atrium; RV = right ventricle; LA = left atrium; LV = left ventricle

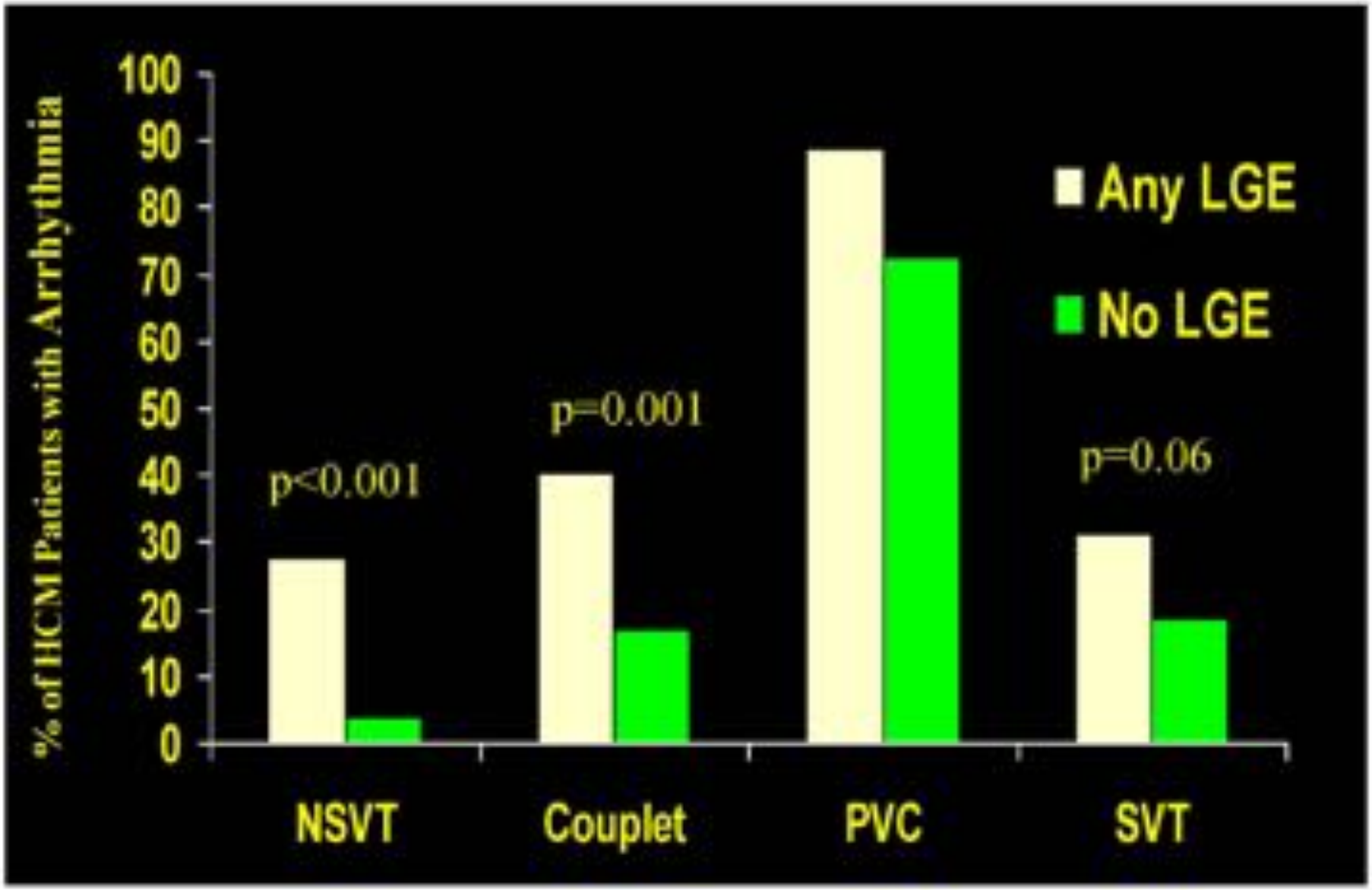

Figure 7 Prevalence of arrhythmia on 24-hour Holter ECG with respect to presence of late gadolinium enhancement in patients with HCM. Adapted with permission, from Adabag et al.[93]. ECG = electrocardiogram; HCM = hypertrophic cardiomyopathy; LGE = late gadolinium enhancement; NSVT = nonsustained ventricular tachycardia; PVC = premature ventricular contraction; SVT = supraventricular tachychardia

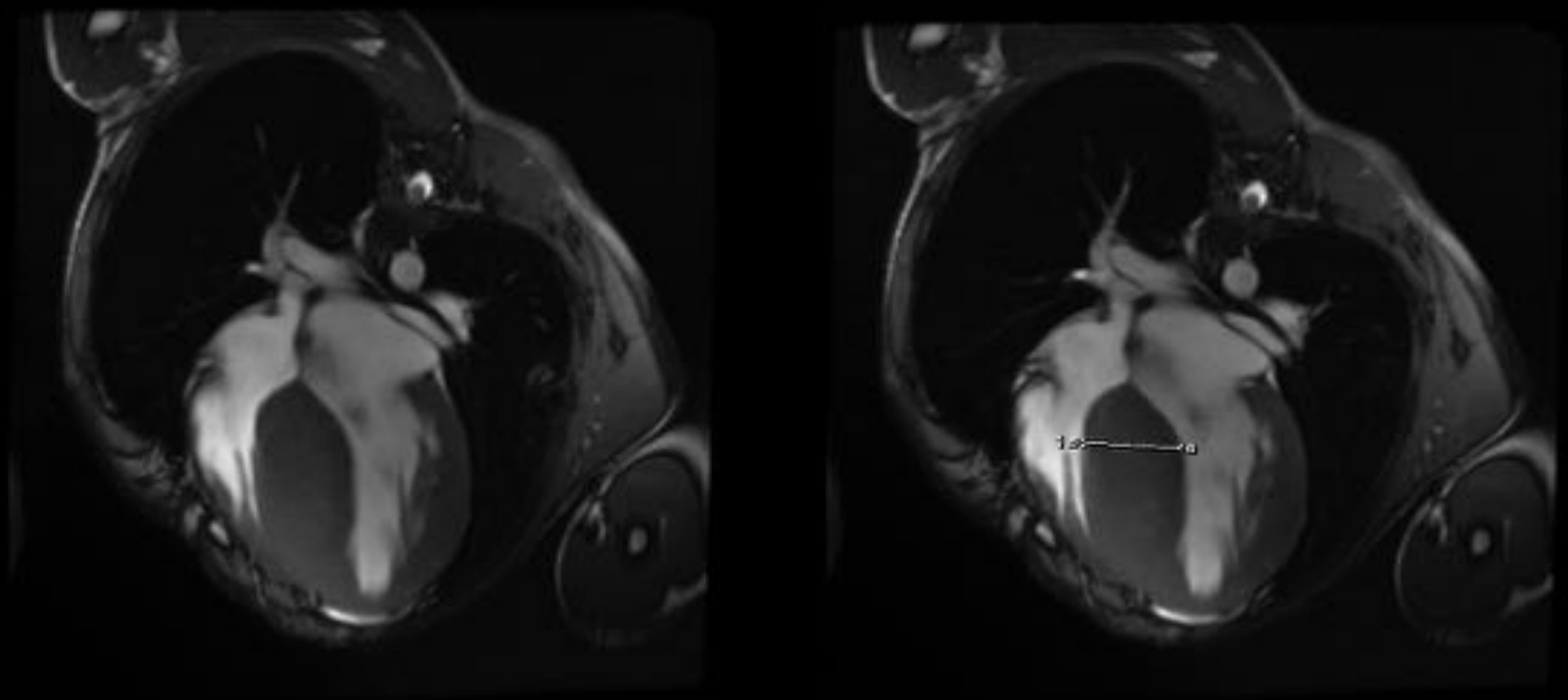

IVS 41 mm

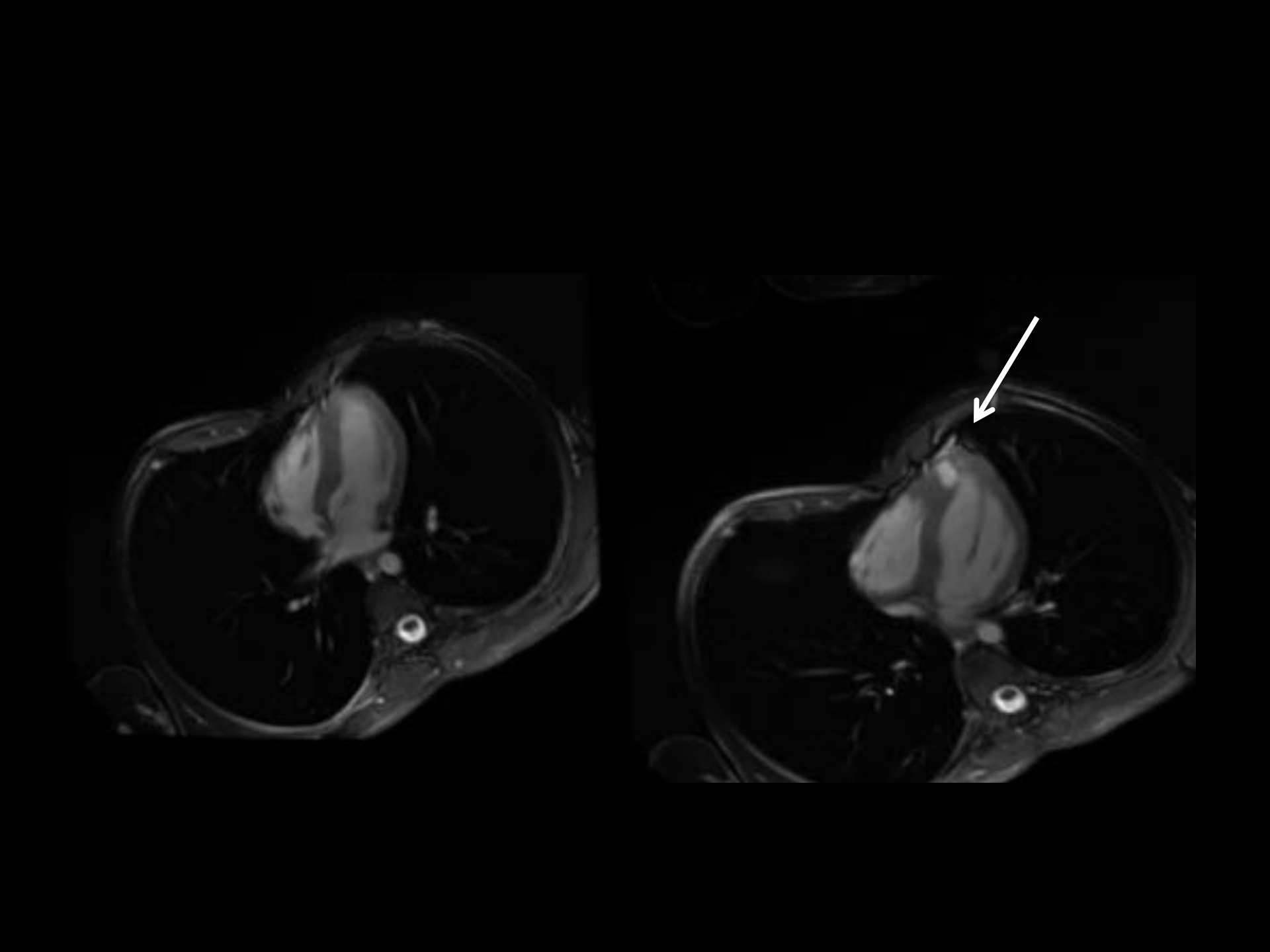

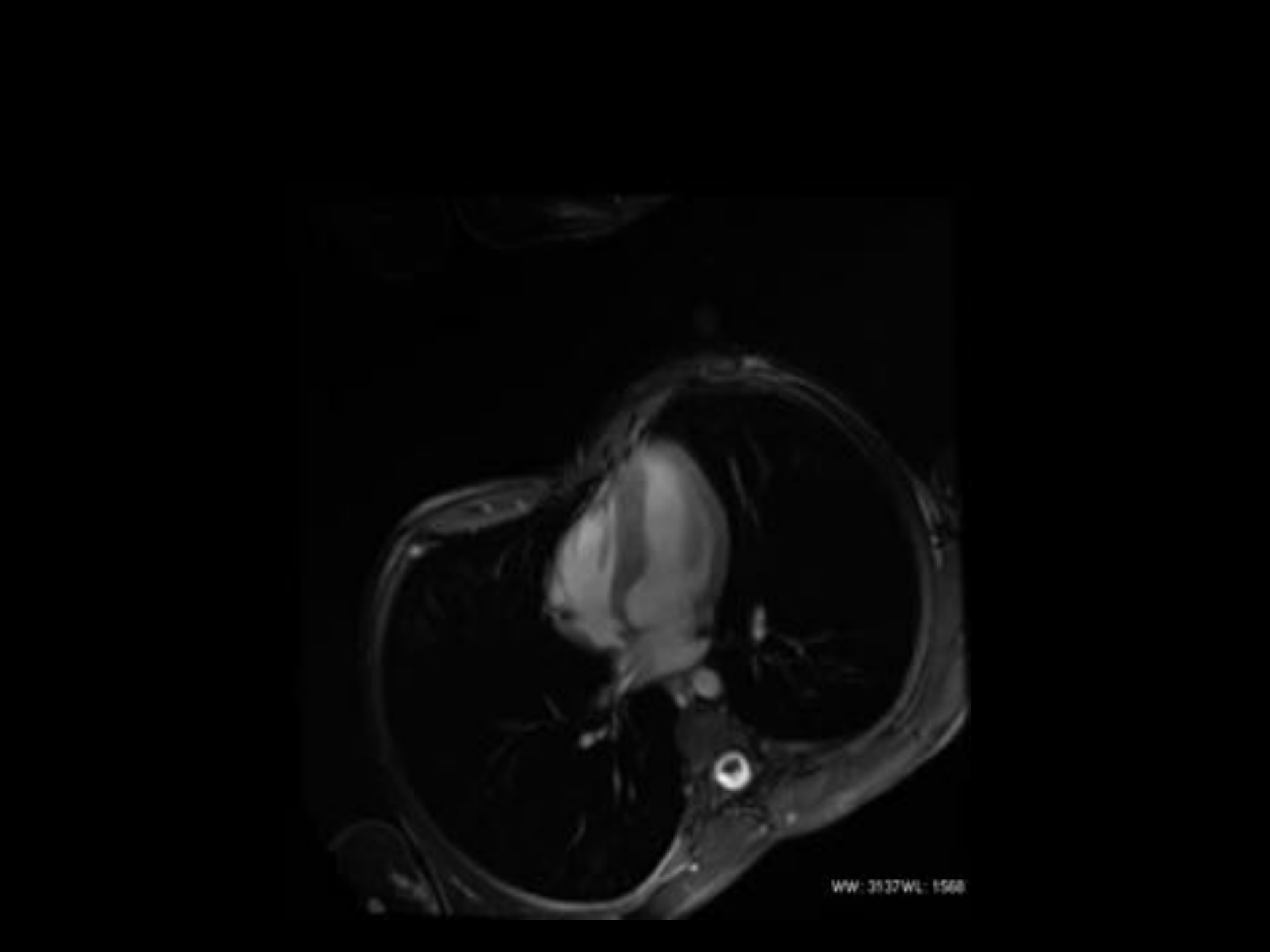
WW: 3137WL: 1568

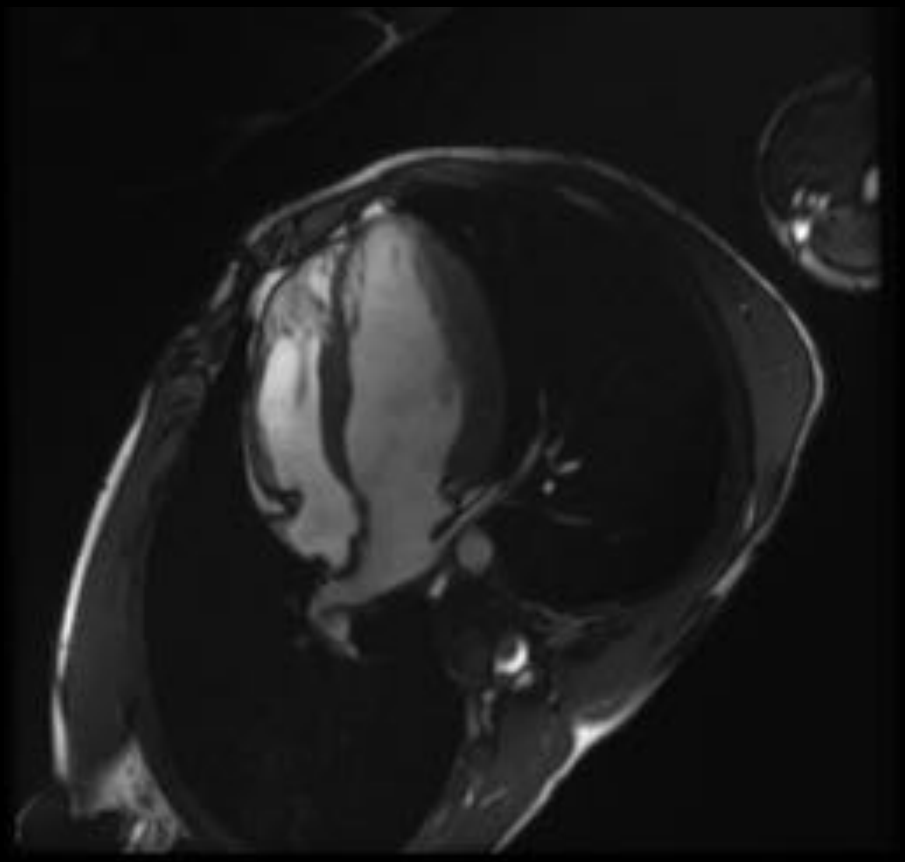

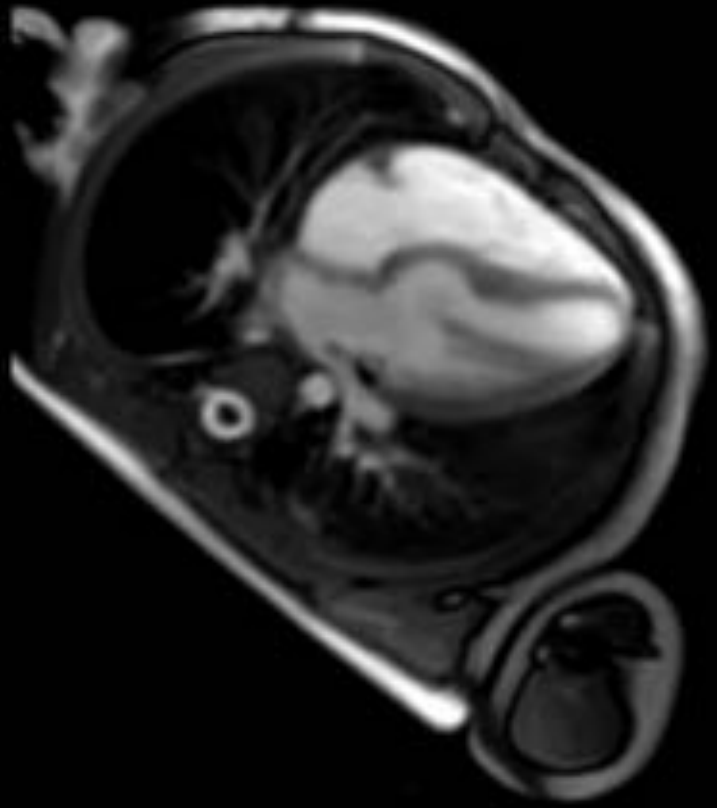

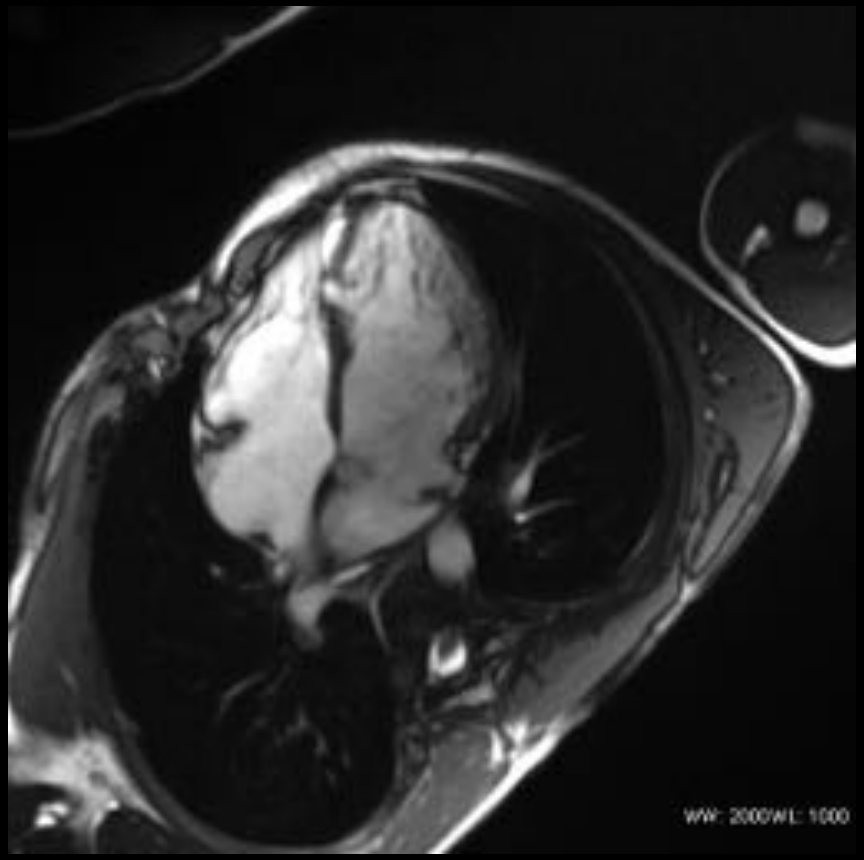

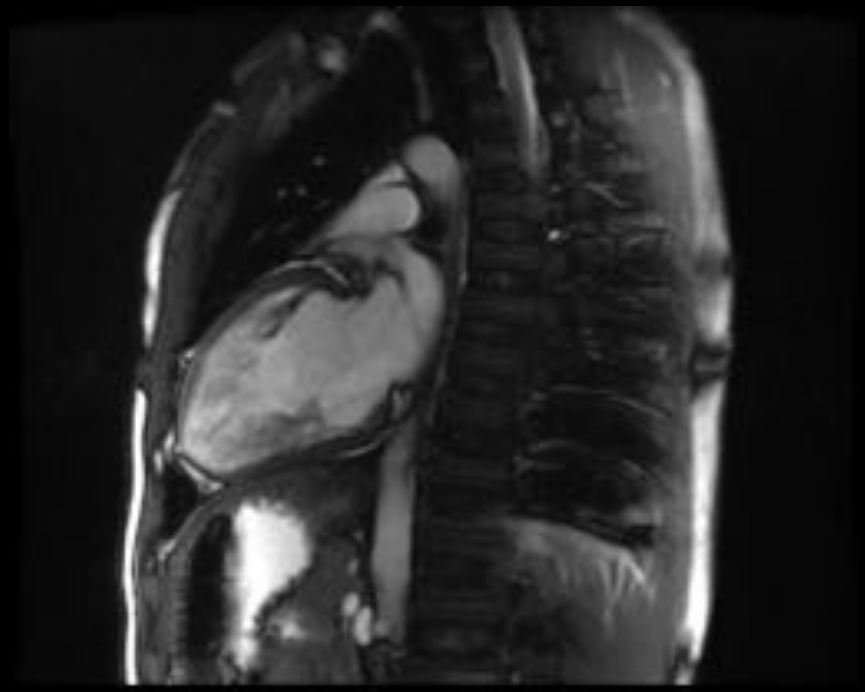

WW: 2000WL: 1000

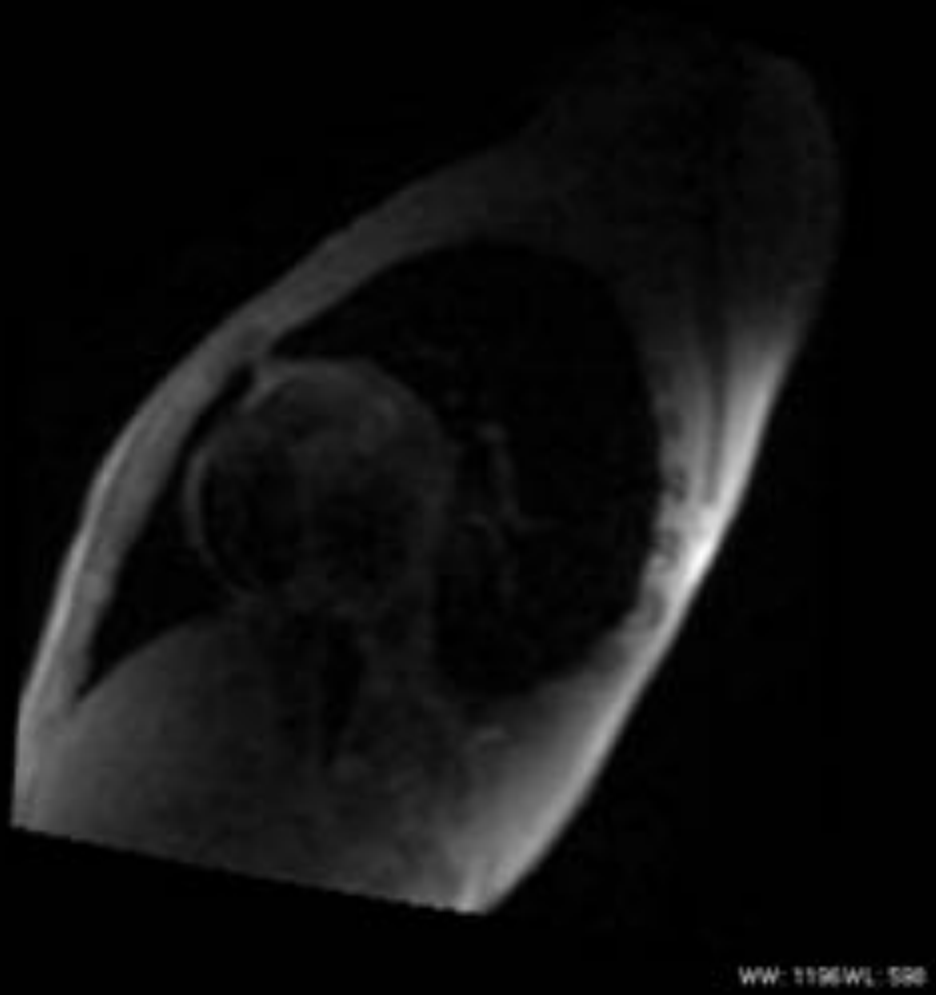
WW: 1196 WL: 598

Tissue analysis

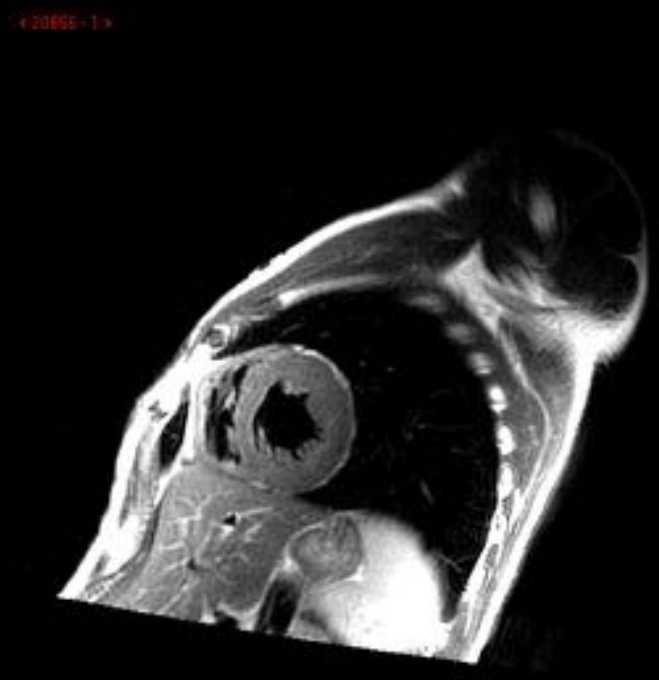

T2 sang noir

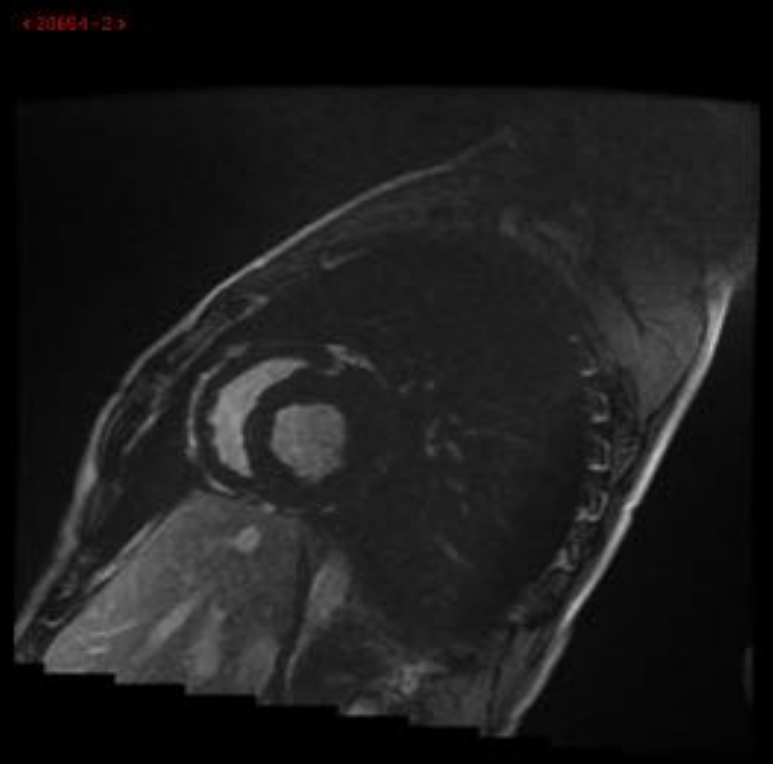

LGE

Fibrose

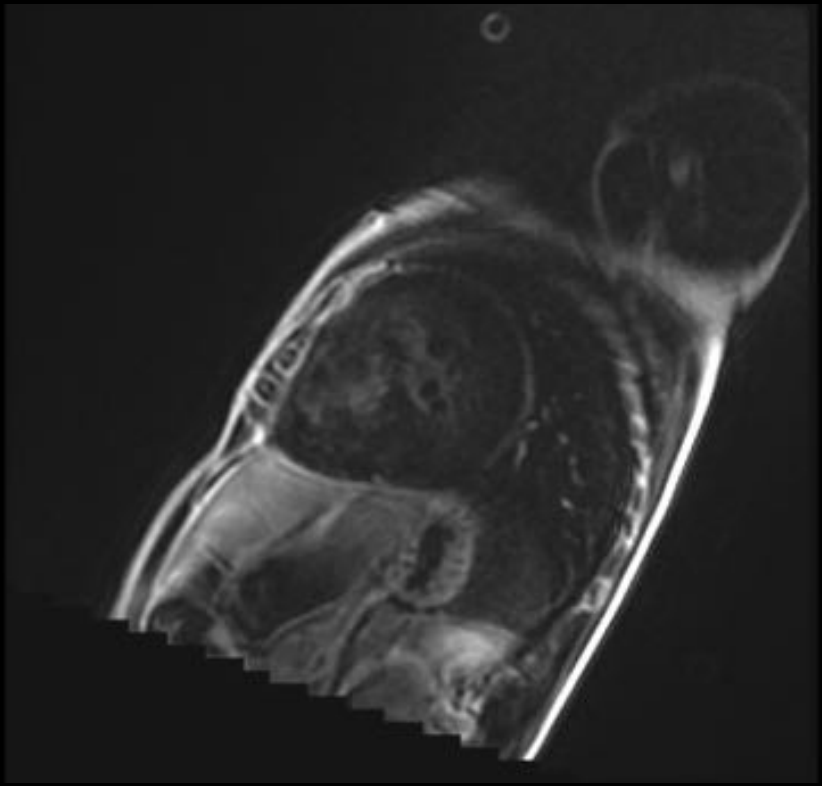

LGE

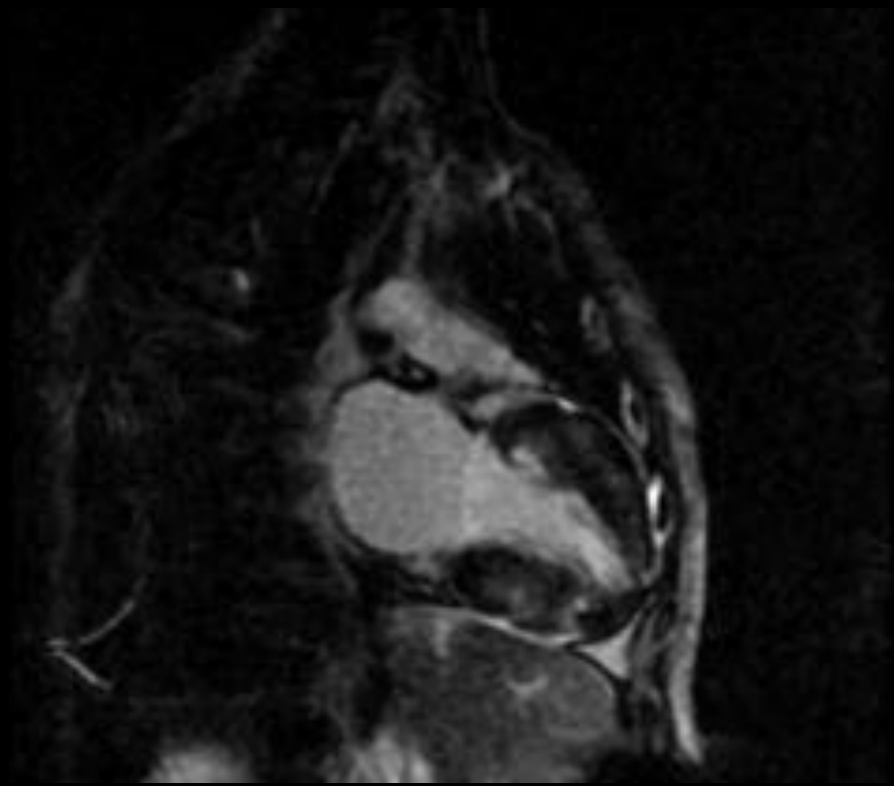

LGE

Progression: 2012

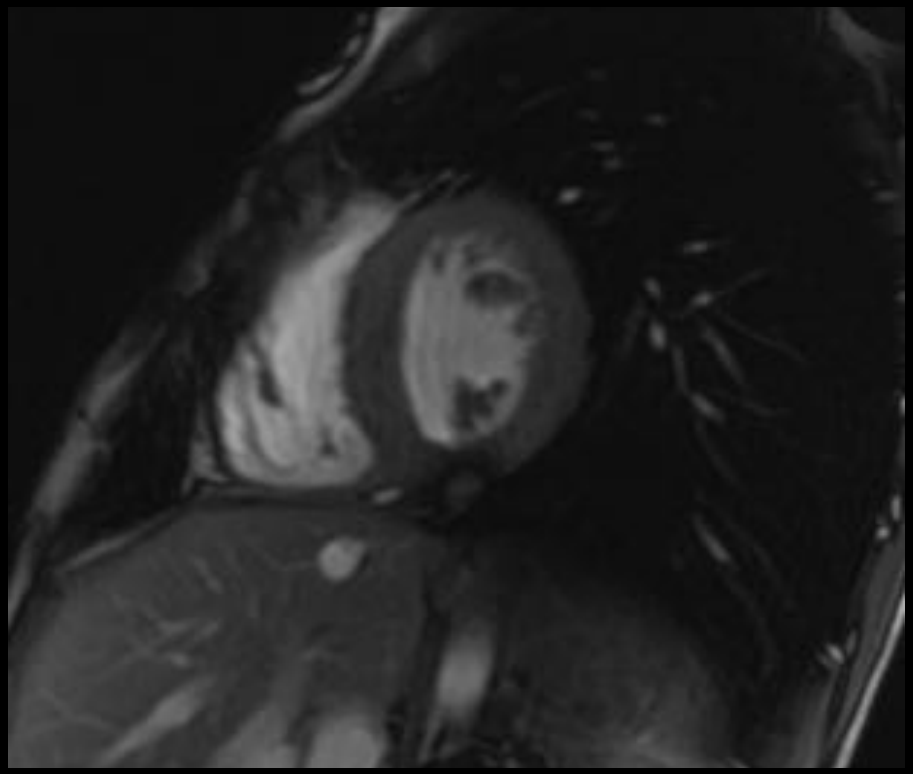

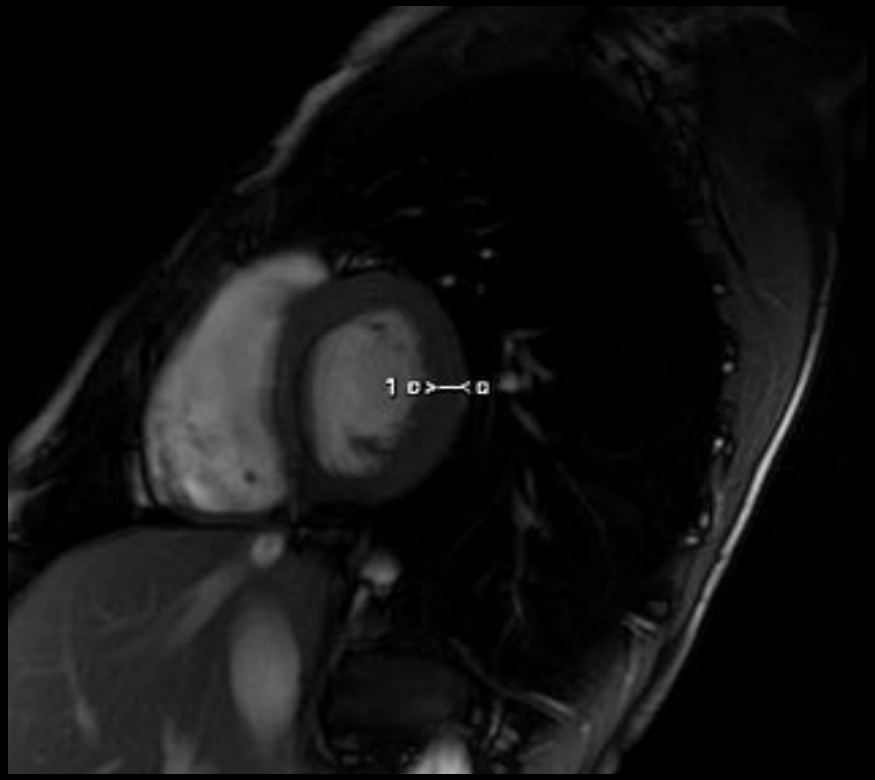

LW 6.7 mm

Progression: 2013

IVS 12 mm, LW 10.5 mm

Progression: 2012

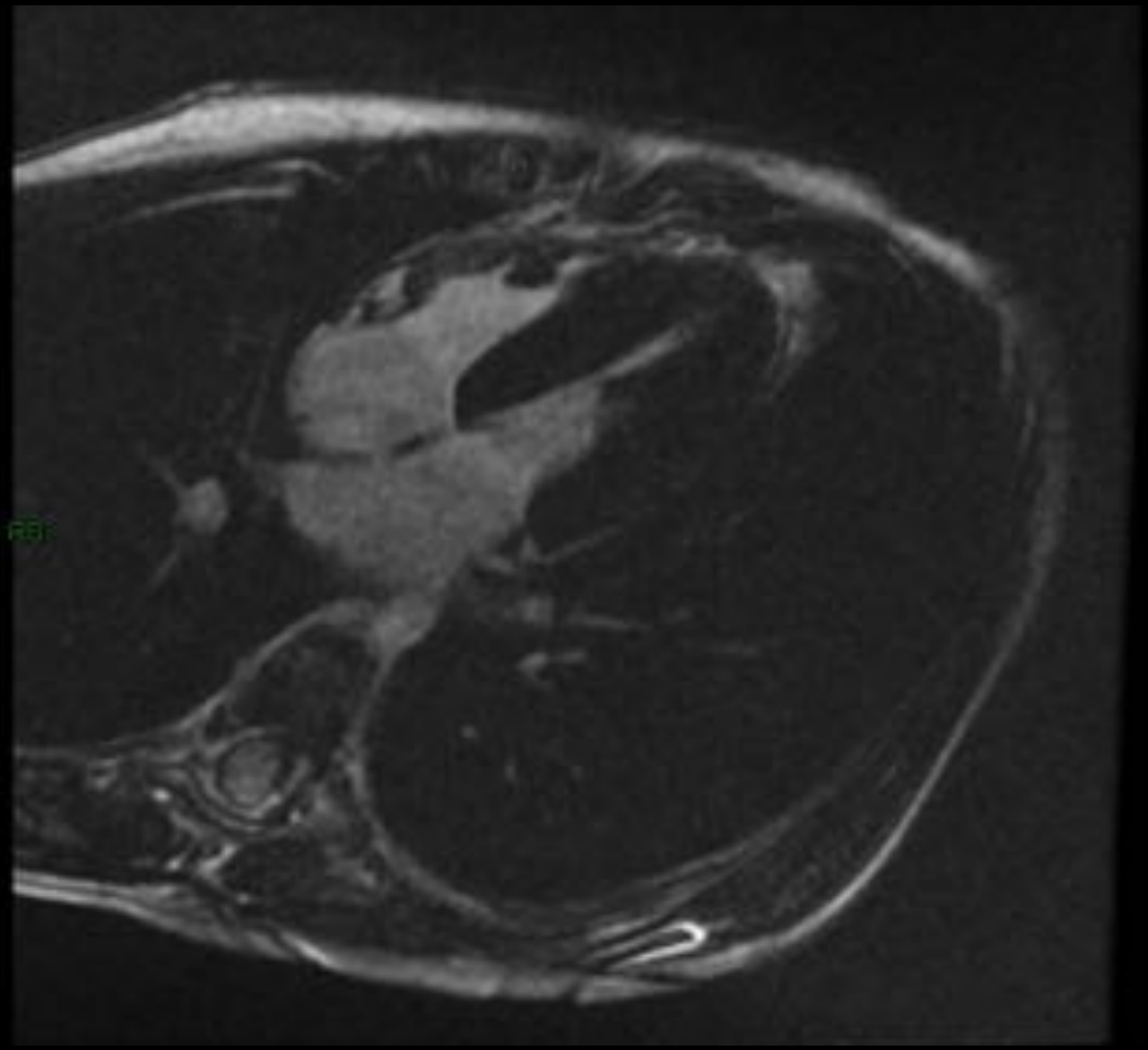

Tumeurs

TABLE 1: Cardiac MRI Findings of Cardiac Tumors

Tumor	Morphology	Most Common Location	Imaging Sequence				
			Steady-State Free Precession	T2-Weighted	Fat Saturation	T1-Weighted Before / After Contrast Administration	Delayed Enhancement
Benign							
Myxoma	Lobular, pedicle	Left atrium, intracavitary, interatrial septum	Usually mobile	High	No change	Isointense / moderate (heterogeneous)	High (heterogeneous)
Lipoma	Smooth	Any chamber, intra-myocardial or intracavitary	May be mobile	Low	Signal dropout	High / minimal	None
Papillary fibroelastoma	Smooth, pedicle	Valvular	Usually mobile	High	No change	Isointense / high	High
Fibroma	Smooth, calcification, broad base	Ventricles, intramyocardial	Intramyocardial	Low	No change	Isointense / minimal	Intense
Rhabdomyoma	Smooth, broad base	Ventricles, intramyocardial	Intramyocardial	High	No change	Isointense / moderate	High
Hemangioma	Lobular, broad base	Any chamber, intracavitary	Usually mobile	High	No change	Isointense / intense	None
Malignant							
Angiosarcoma	Lobular, broad base	Right atrium	Intramyocardial	Heterogeneous	No change	Isointense / heterogeneous	Heterogeneous
Undifferentiated sarcoma	Lobular, broad base	Left atrium	Intramyocardial, involves valves	Isointense	No change	Low	—
Leiomyosarcoma	Lobular, broad base	Left atrium, posterior wall	Intramyocardial	High	No change	Isointense / high	—
Fibrosarcoma	Lobular, broad base	Left atrium, pericardium	Intramyocardial	—	No change	Isointense / —	—
Liposarcoma	Lobular, broad base	Left or right atrium, pericardium	Intramyocardial	—	Signal dropout	Isointense / —	—
Osteosarcoma	Lobular, calcification	Left atrium	Intramyocardial	High	No change	Isointense / —	—
Lymphoma	Lobular, pericardial effusion	Right atrium	Intramyocardial	High	No change	Isointense / variable	High
Metastases	Smooth, lobular	Variable, pericardial effusion	Intramyocardial	High	No change	Low	High

Fibrome

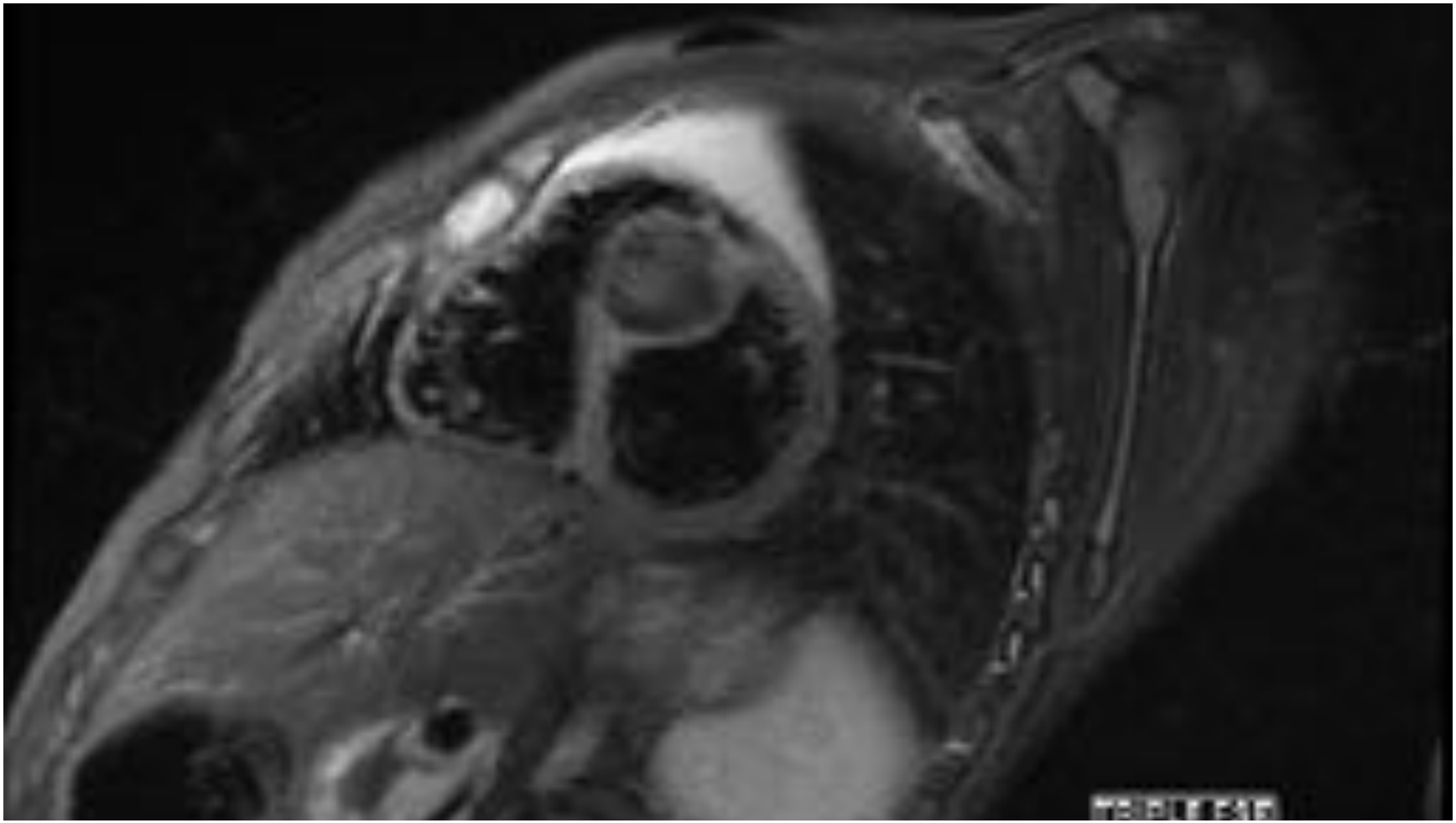

Fibrome

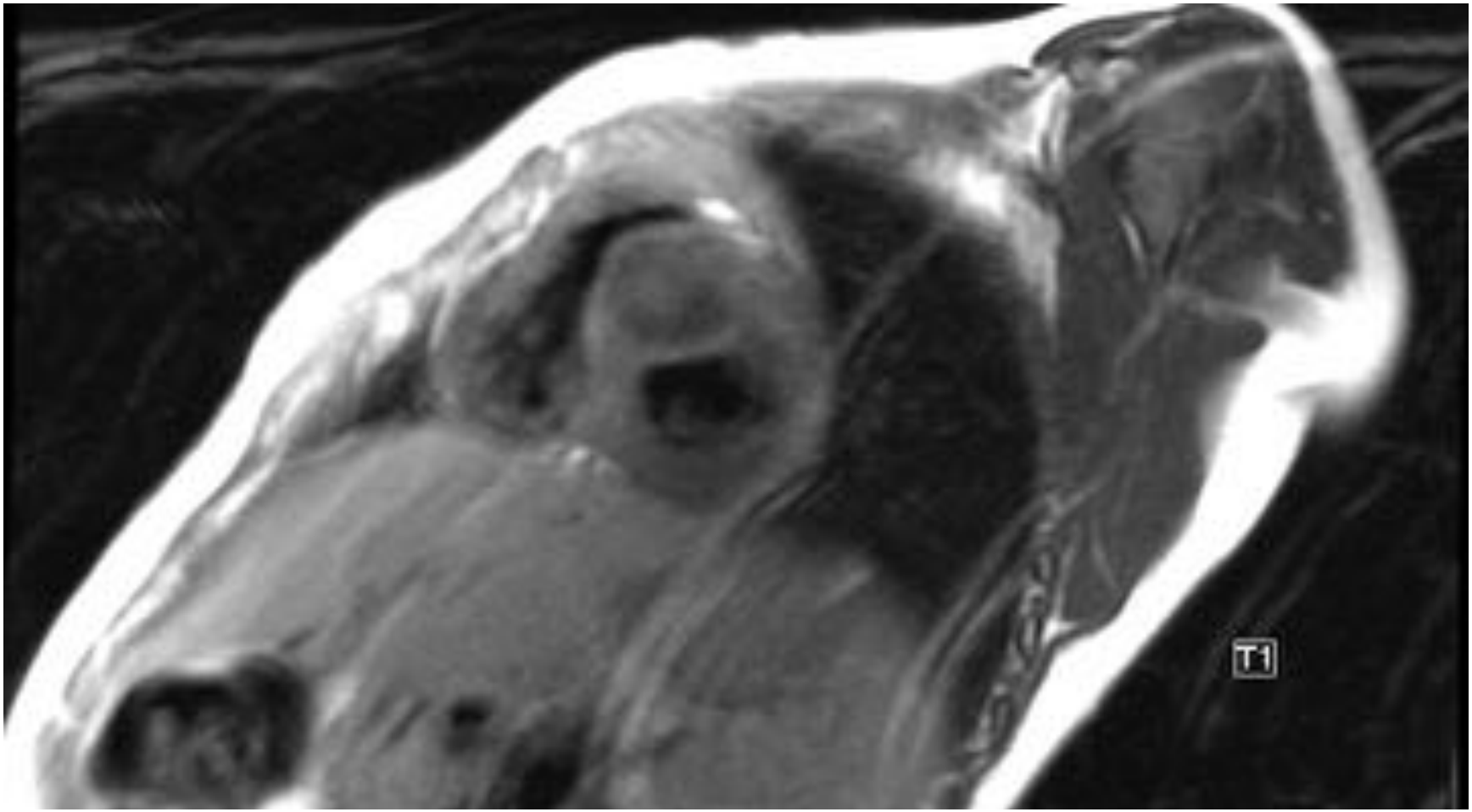

Fibrome

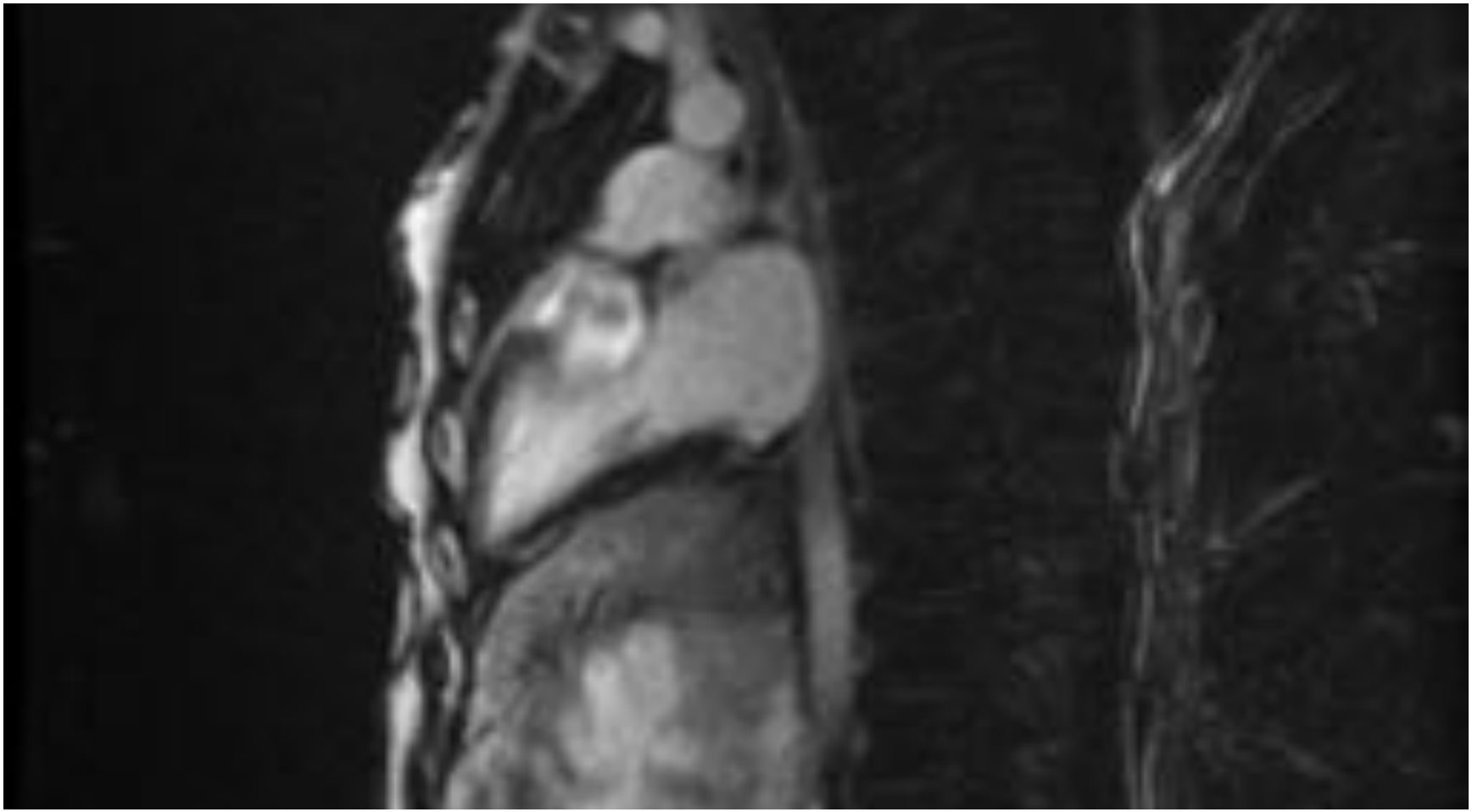

Fibrome

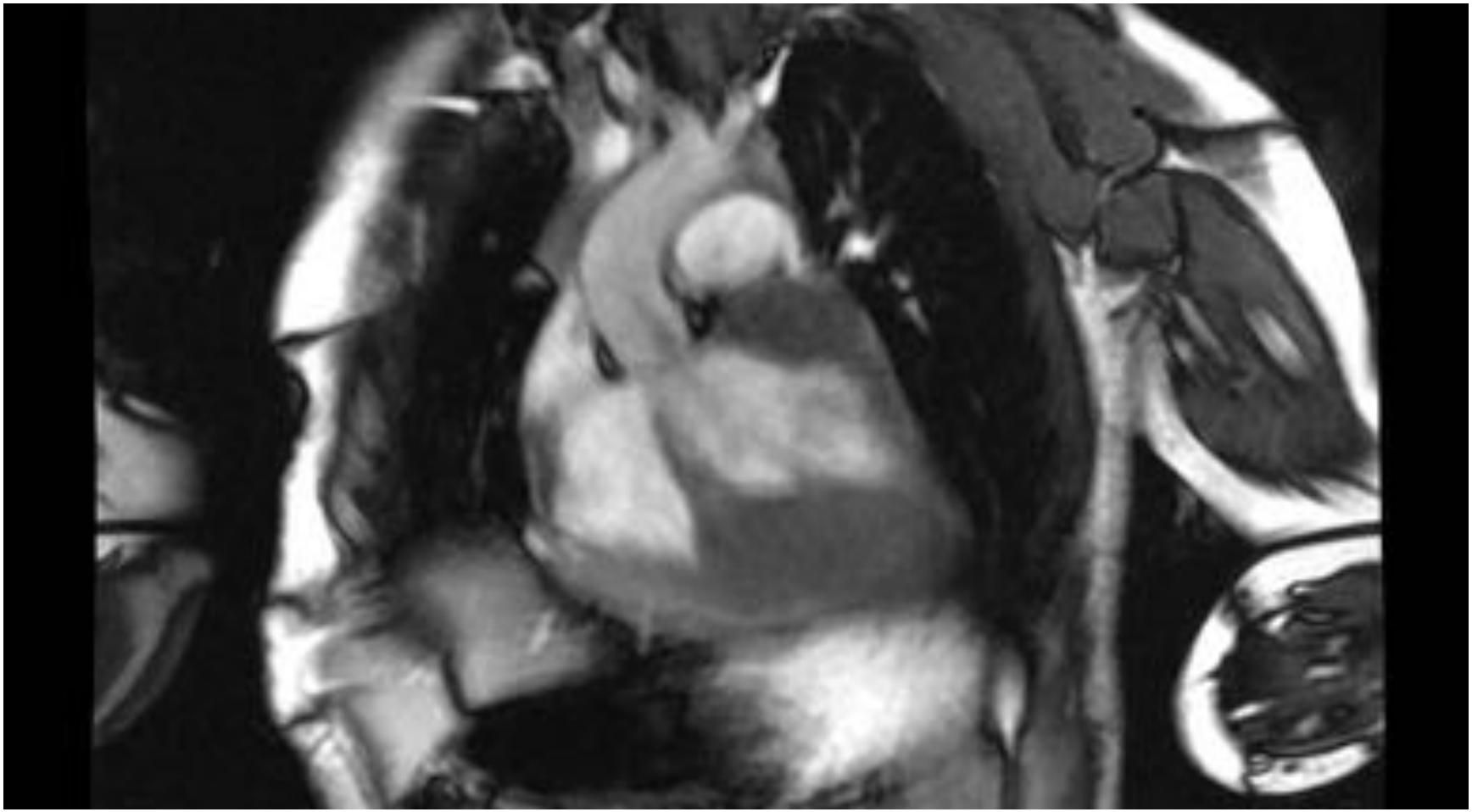

Fibrome

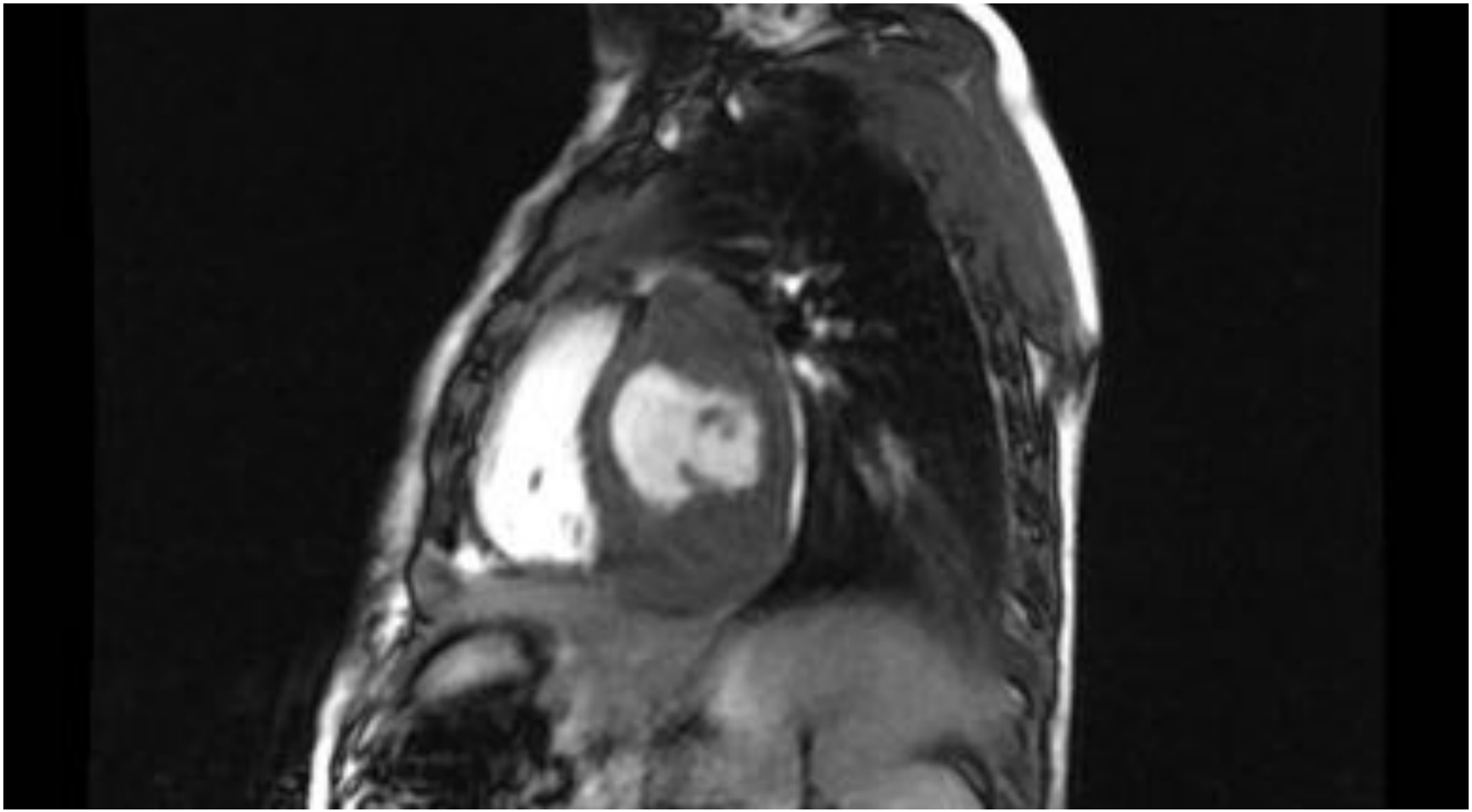

Fibrome

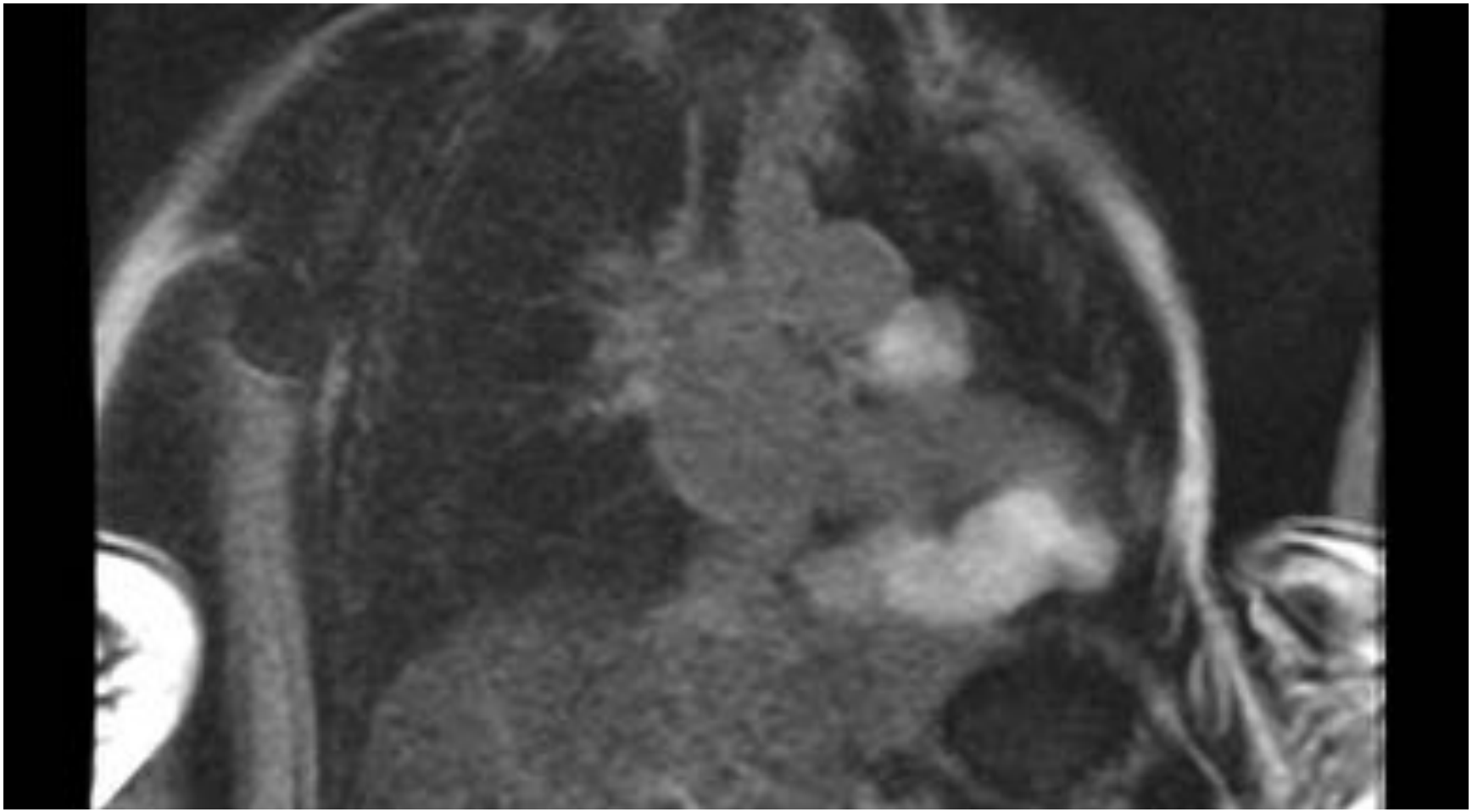

Fibrome

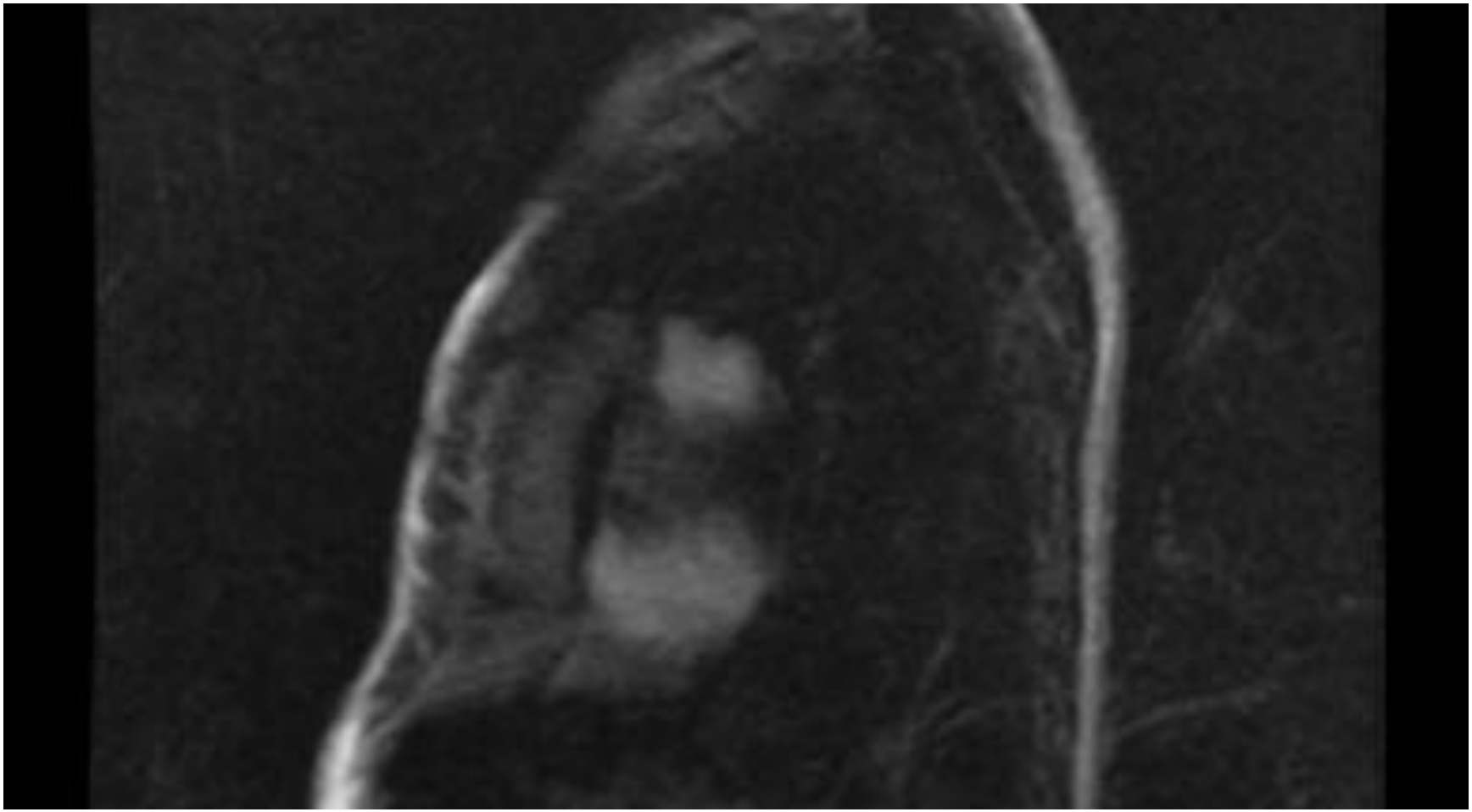

Fibrome

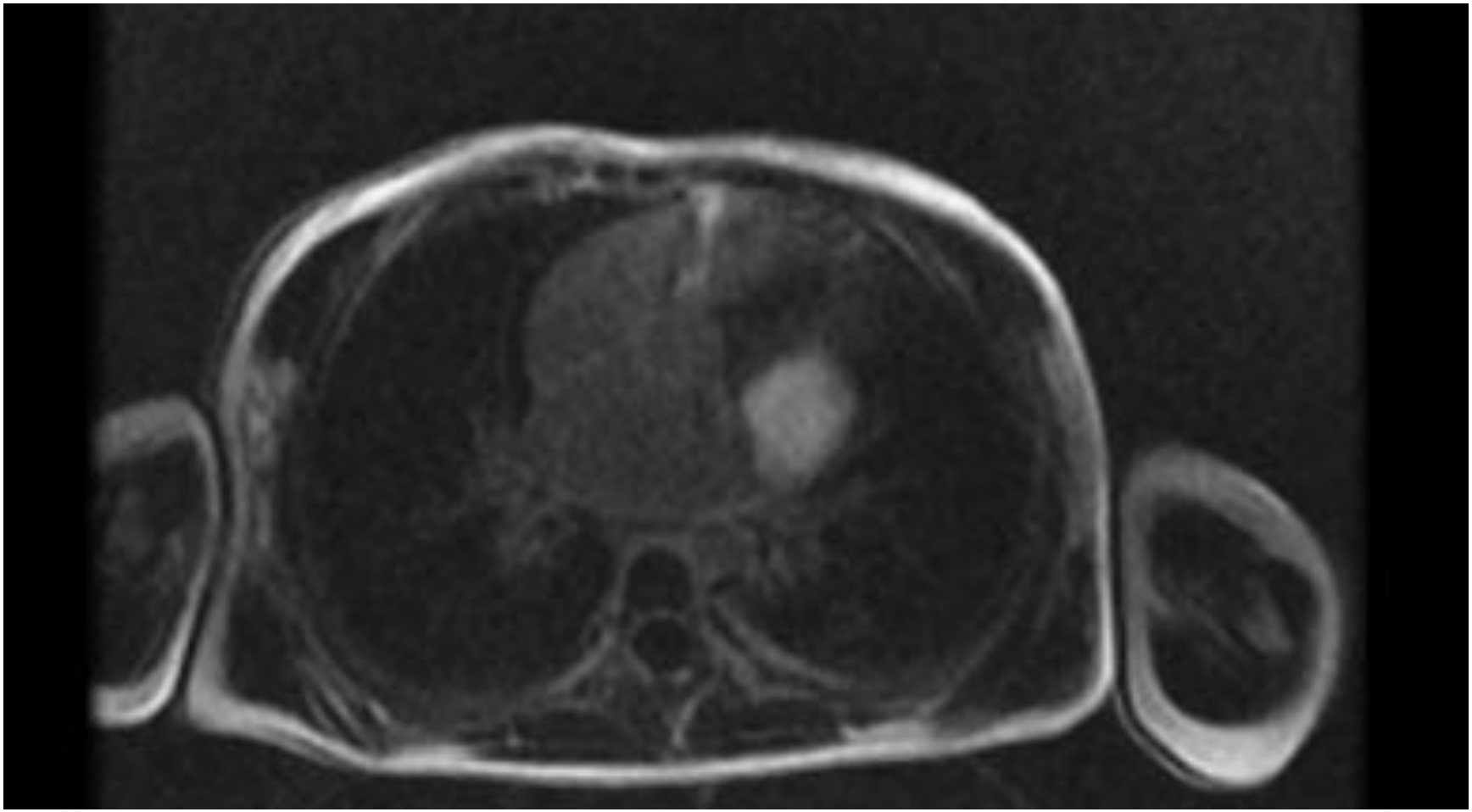

Rabdomyome

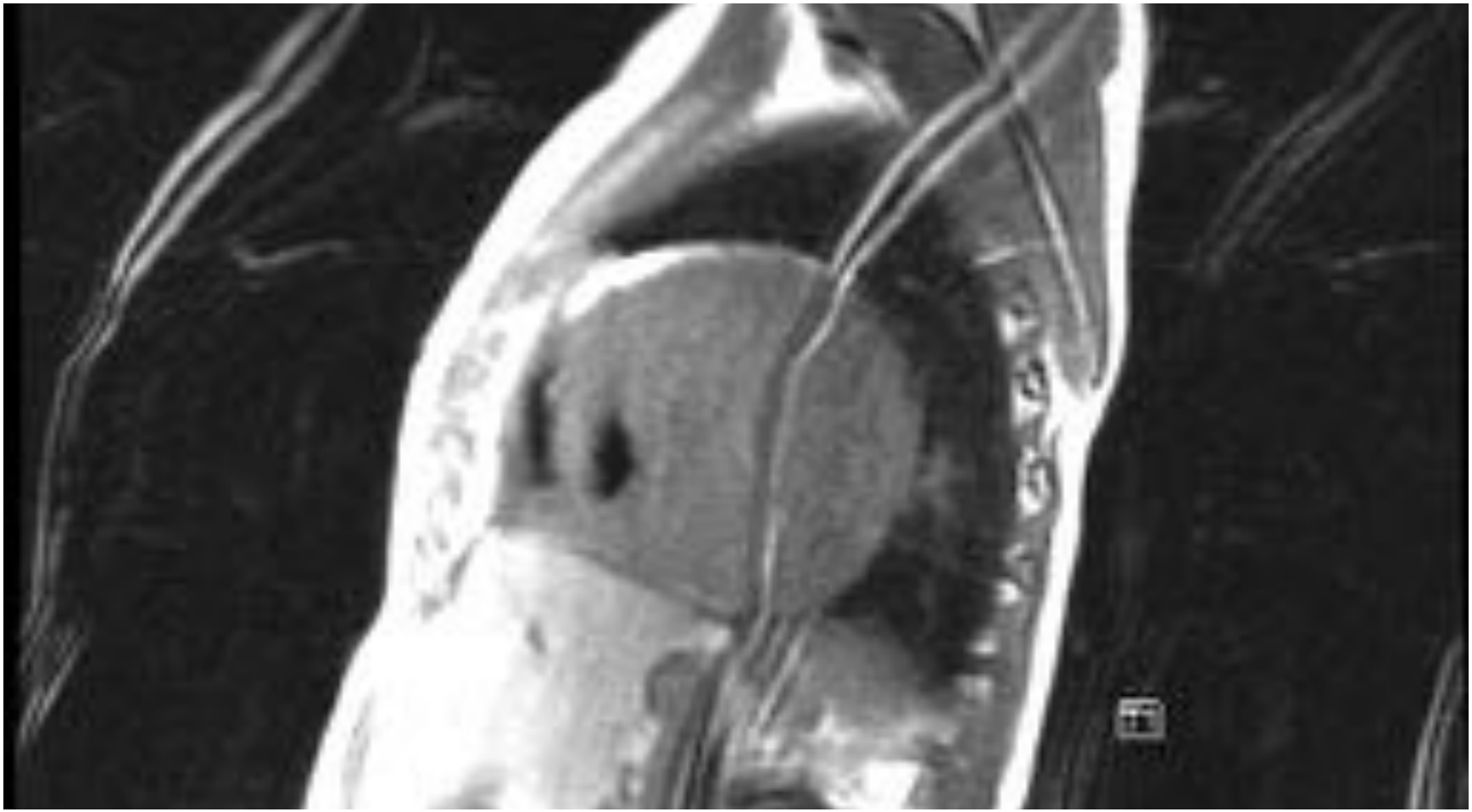

Rabdomyome

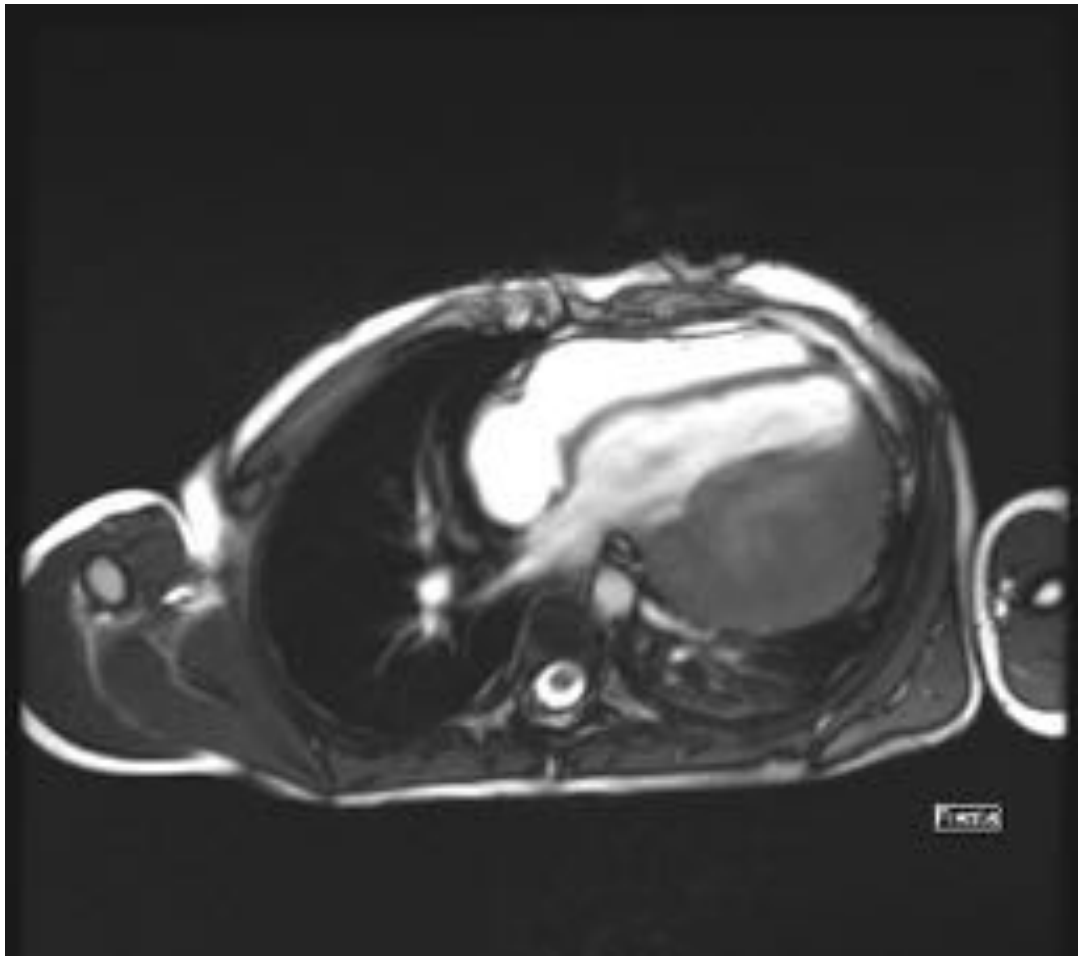

Rabdomyome

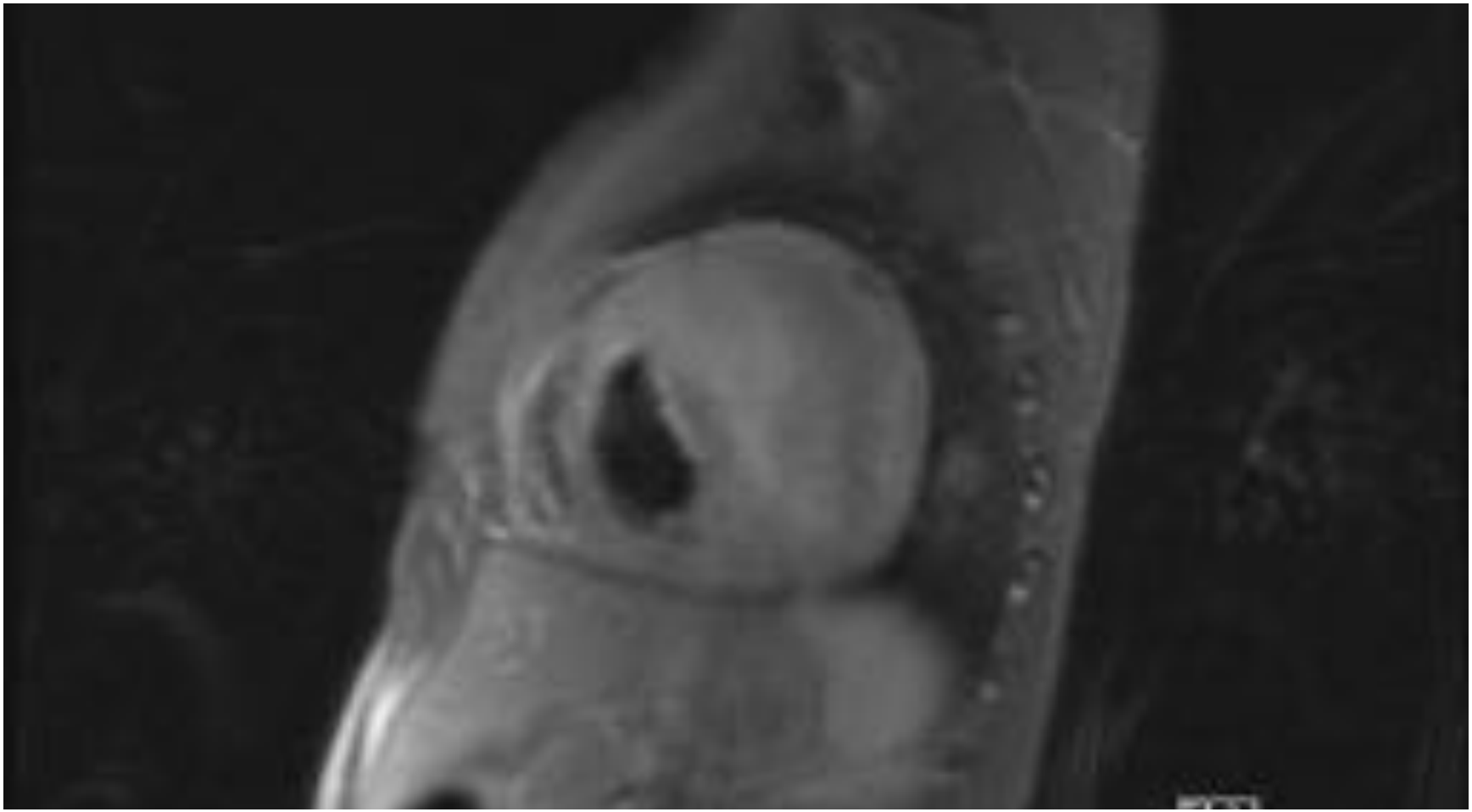

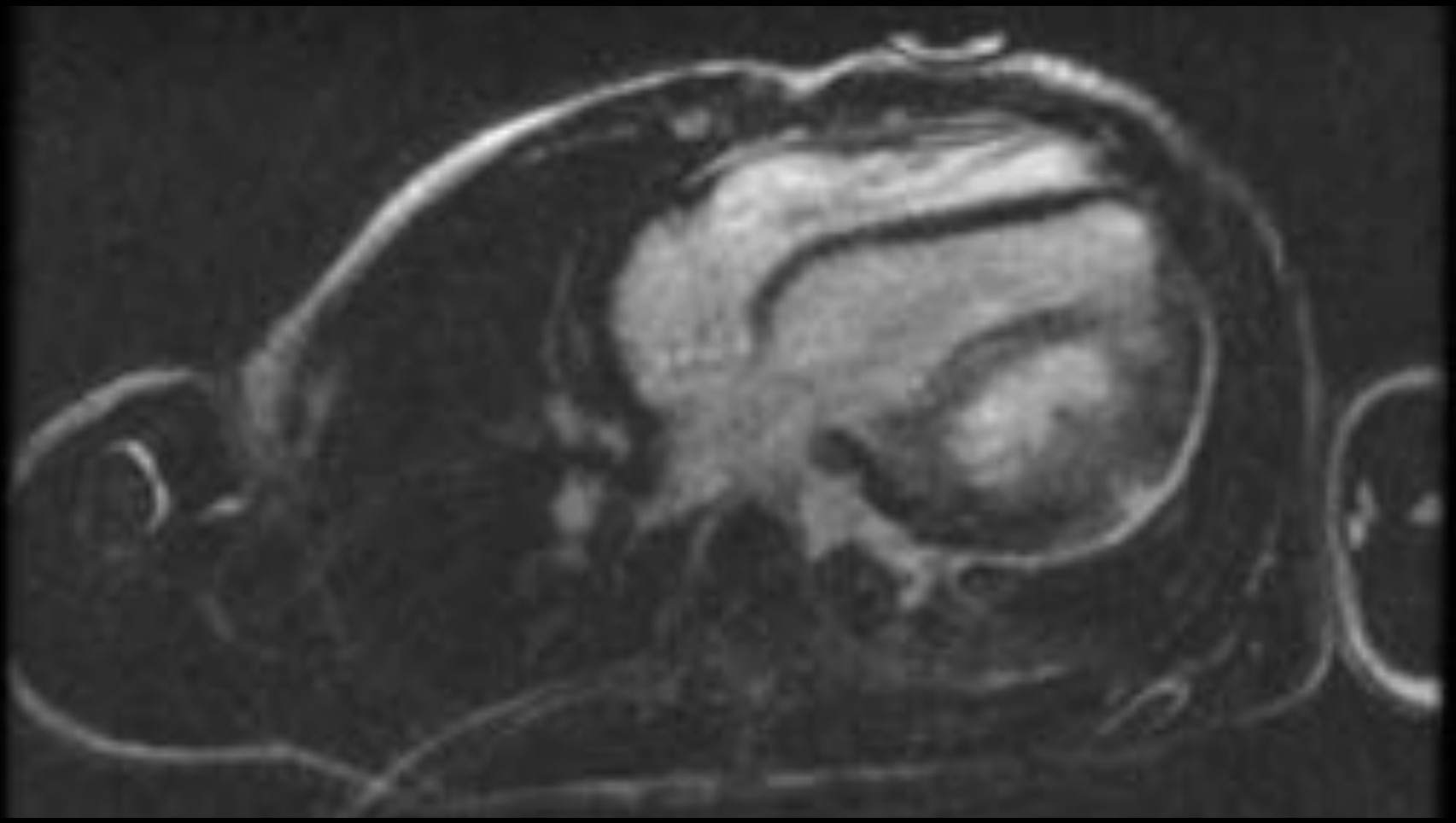

Tumeurs

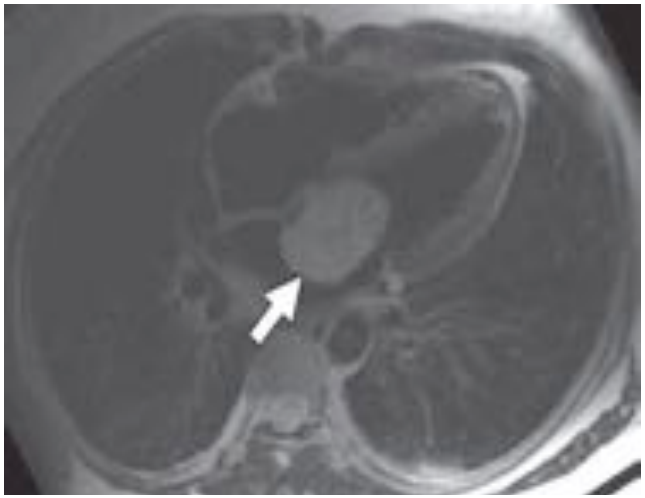

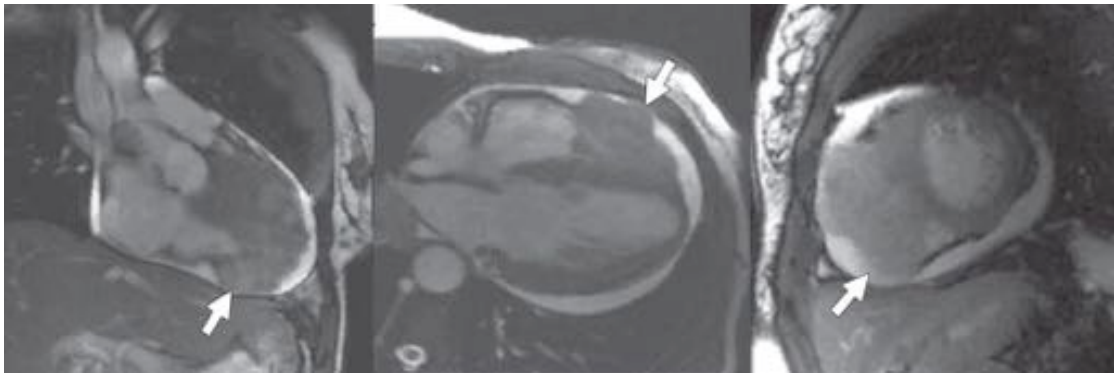

Fig. 1—Examples of sequences used for cardiac tumor assessment on cardiac MRI.
A, 62-year-old man with progressive dyspnea. Axial fast spin-echo image quickly allows identification of mass (*arrow*), enabling subsequent sequences to be targeted to left atrium in this case. Left atrial myxoma was proven at surgery.
B, 43-year-old woman with previously resected cutaneous malignant melanoma. Two-chamber (*left*), four-chamber (*middle*), short-axis (*right*) steady-state free precession images. Tumor (*arrows*) is accurately located using all three image planes. Presumed diagnosis is malignant melanoma metastases. (See also Fig. S1, cine images, in supplemental data at www.ajronline.org.)

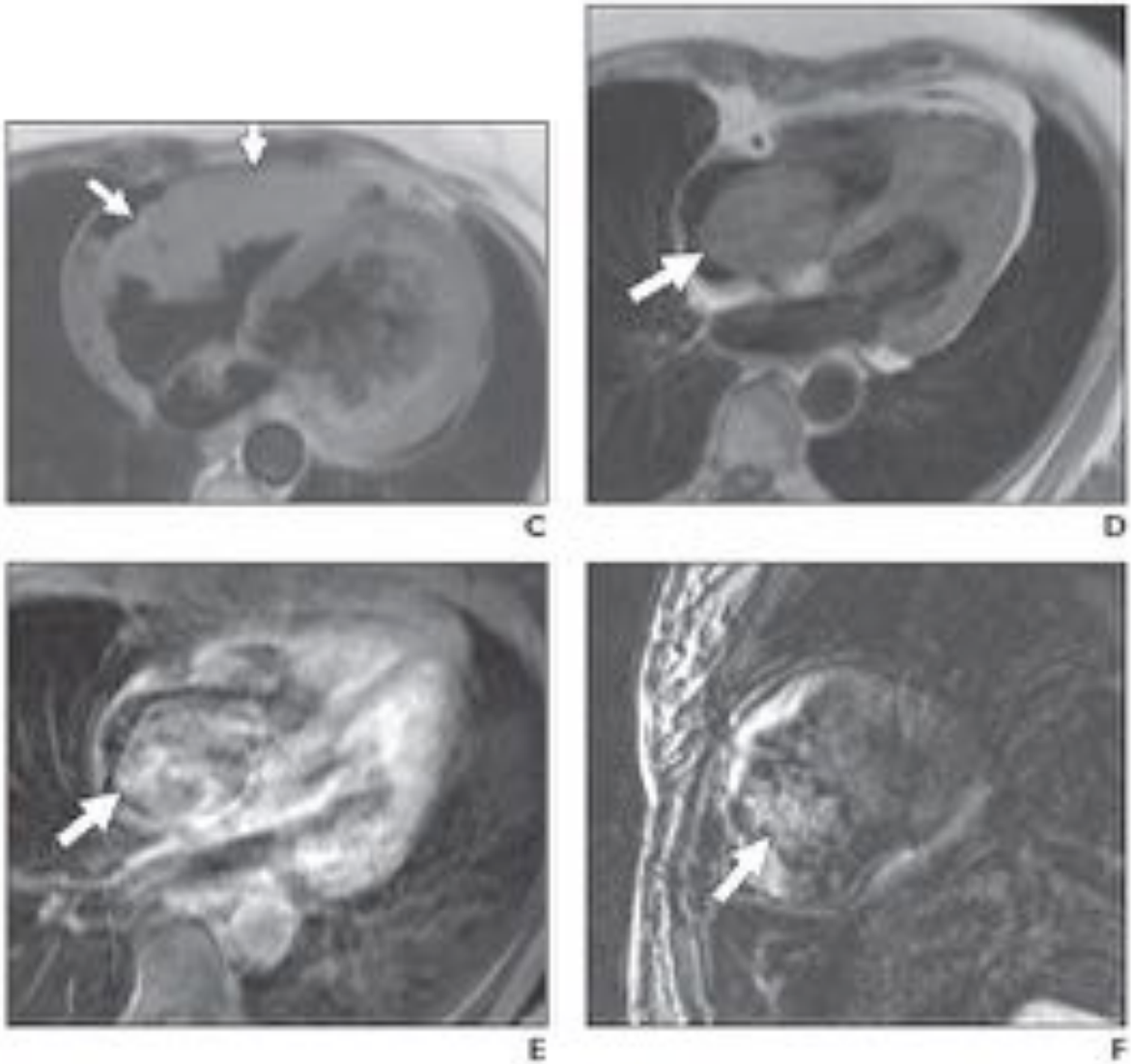

Fig. 1 (continued)—Examples of sequences used for cardiac tumor assessment on cardiac MRI.
C, 42-year-old woman with chest pain and palpitations. Four-chamber T2-weighted image shows high signal in extensive right ventricular free wall mass (arrows). Cardiac lymphoma was proven at biopsy. (See also Figs. S1 and S2, cine images, in supplemental data at www.ajronline.org.)
D and **E**, 47-year-old woman with progressive dyspnea. Axial T1-weighted images before (**D**) and after (**E**) administration of gadolinium show heterogeneous enhancement of right atrial mass (arrows). Right atrial myxoma was proven at surgery.
F, 43-year-old woman with previously resected cutaneous malignant melanoma (same patient as in **B**). Short-axis delayed enhanced sequence shows enhancement (arrow) of tumor.

Role de l'IRM dans les CC

CMR acquisition options in CHD (see accompanying notes)		1. Multislice scouts ×3	Cines and stacks of cines									Velocity mapping						3D SSFP		CEMRA			23. Late Gd enhancement	24. Myocardial perfusion
			2. VLA and HLA	3. Short axis stack	4. 4ch, LVOT(s), AoV	5. Aortic arch cine(s)	6. RVOT cines	7. PA cines	8. Transaxial stack	9. Coronal stack	10. Atrial SA stack	11. Mitral stack	12. MPA flow	13. Aortic flow	14. Jet velocity series	15. ASD flow area	16. TR jet area	17. PR jet area	18. Global 3D	19. Coronary MRA	20. Pulmonary arteries	21. Pulmonary veins	22. Aortic Arch		
Recommended																								
Can be useful																								
Italics = CMR study recommended																								
Left heart	Mitral regurgitation																							
	Mitral stenosis																							
	Aortic stenosis																							
	Aortic regurgitation																							
	Ross operation																							
	Ao Coarctation																							
	Marfan disease																							
Right heart	Tricuspid regurgitation																							
	Ebstein																							
	DCRV																							
	Fallot, repaired																							
	PS/PR																							
	RV-PA conduit																							
	MAPCAs																							
	Pulmonary hypertension																							
Shunts	ASD																							
	VSD																							
	PAPVC																							
	PDA																							
	B-T shunt (etc.)																							
	Eisenmenger PH																							
TGA	*Mustard/Senning*																							
	Arterial switch op.																							
	Rastelli op.																							
	CCTGA																							
Fontan	*Fontan op.*																							
Complex	*Complex CHD*																							
Coronary artery anomalies																								

Eur Heart J. Apr 2010



Merci pour votre attention…

Analyse tissulaire complexe

SPECTROMETRIE

Principe général de l'IRM

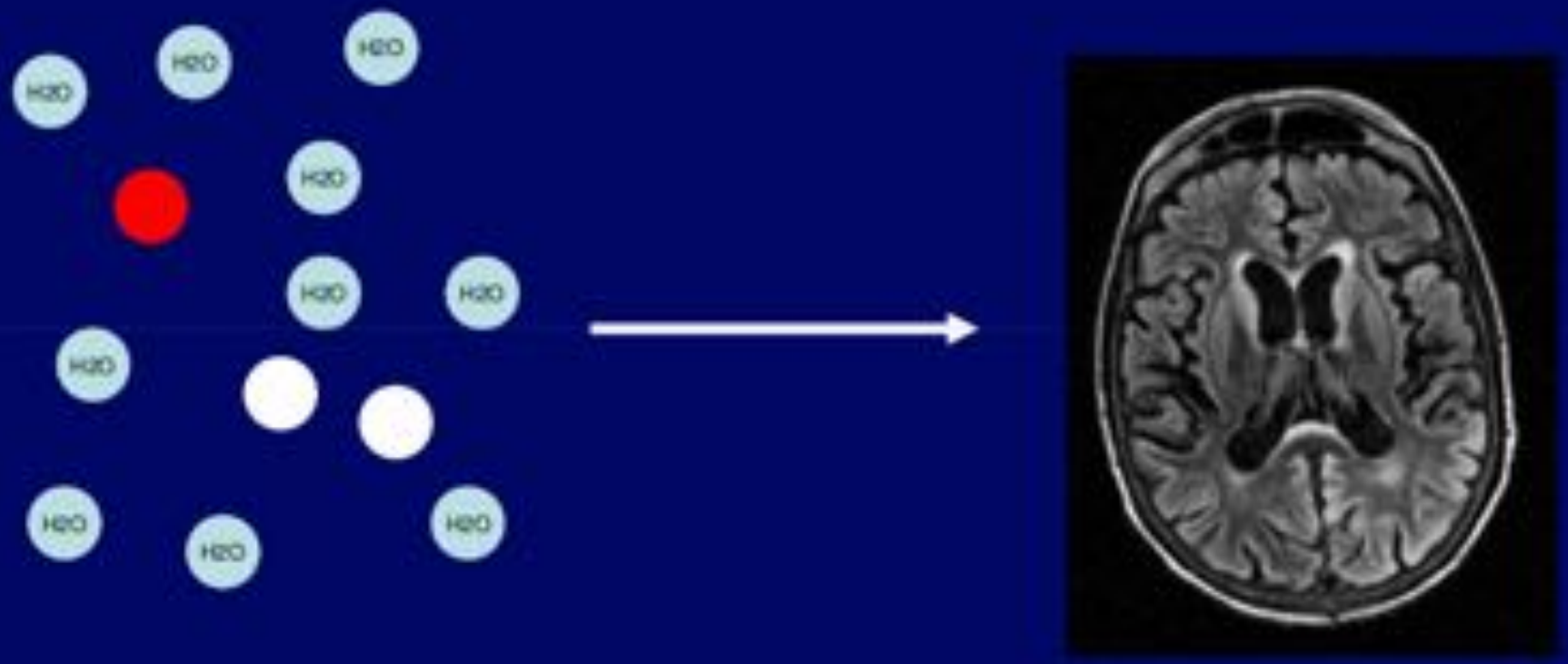

Principe général de la SRM

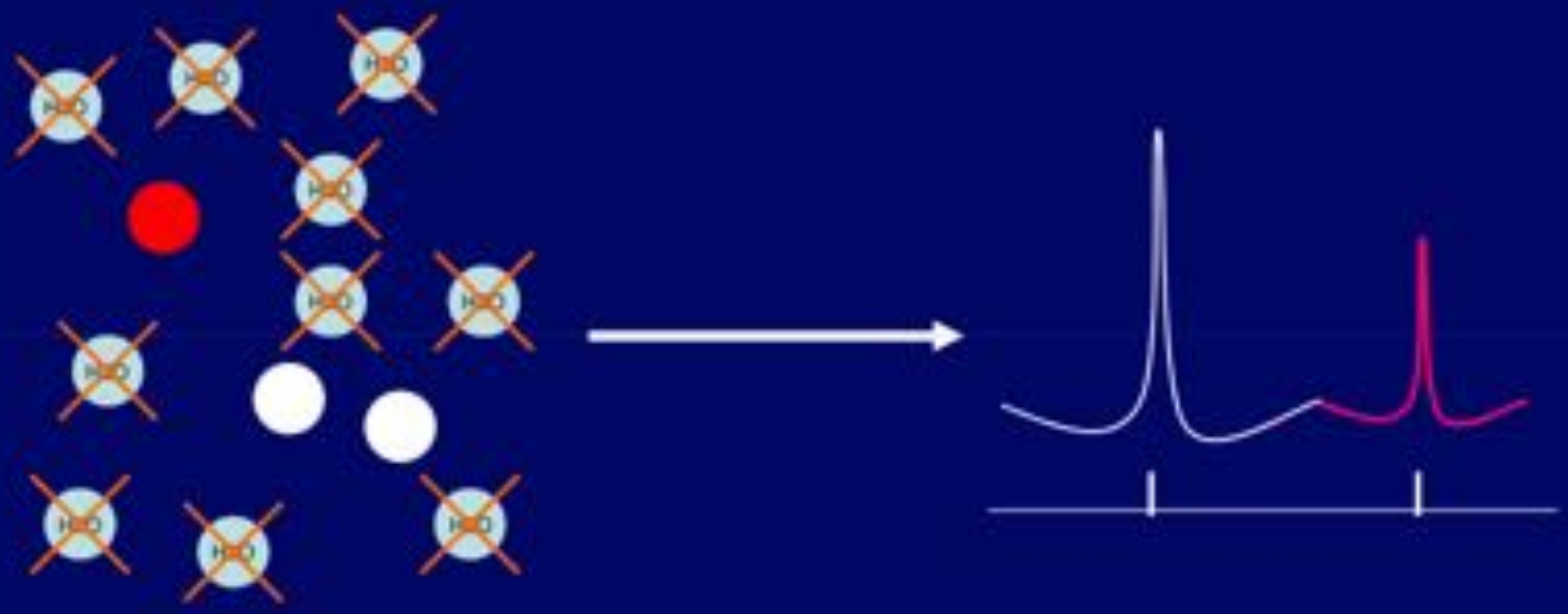

En résumé:

- IRM : recueil du signal des molécules d 'eau

  → image

- SRM :
- suppression du signal de l 'eau
- recueil du signal des molécules dissoutes

  → caractérisation métabolique

- Même appareil, même examen

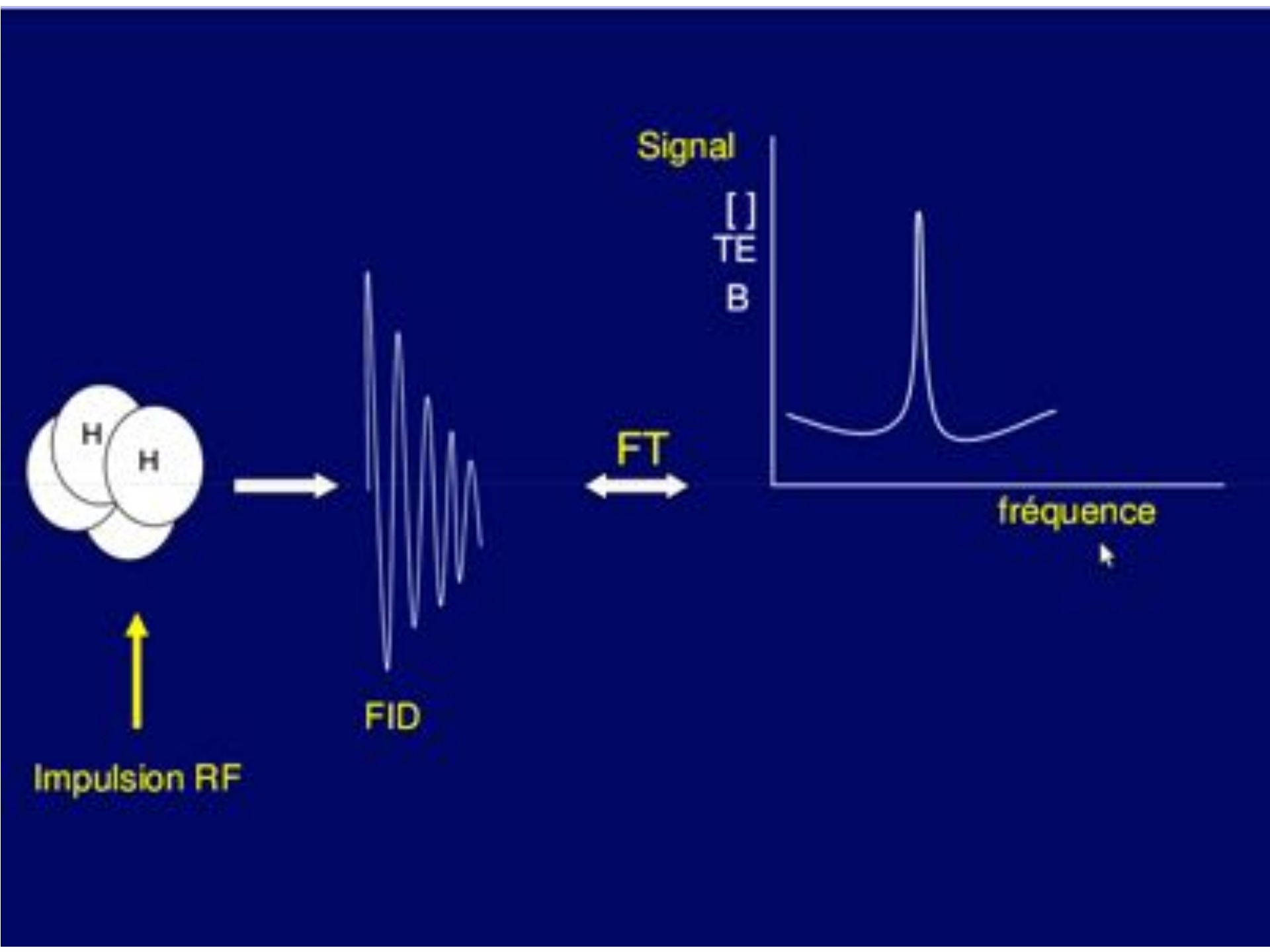
Signal
[ ]
TE
B
H
H
FT
fréquence
FID
Impulsion RF

Principe: utilisation des différences de fréquence de résonance des protons des différentes molécules

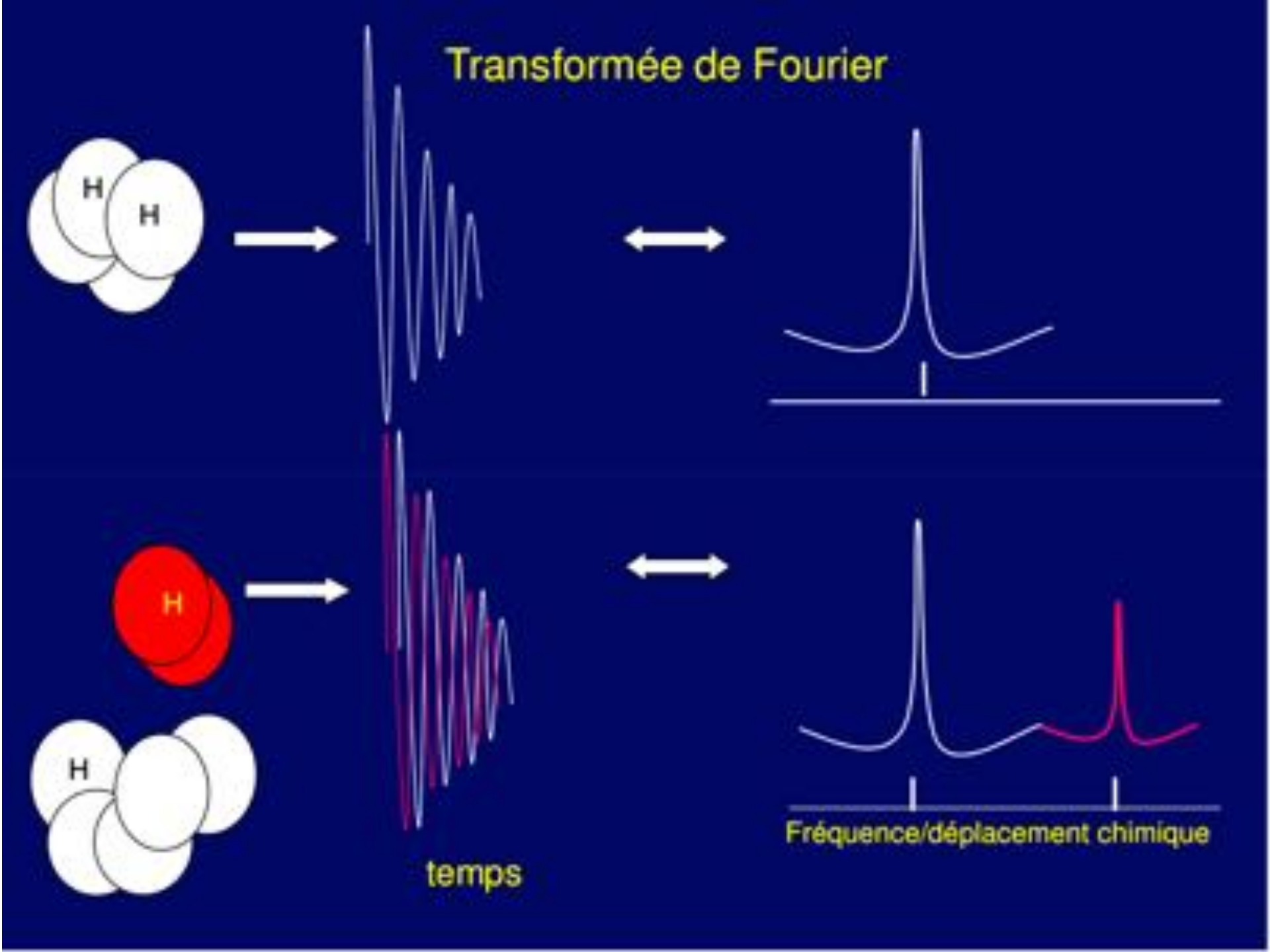
Transformée de Fourier
H
H
H
H
temps
Fréquence/déplacement chimique

NAA (N-Acetyl-Aspartate) : index de souffrance ou de mort neuronale

CHO (Choline) : marqueur des membranes (lésions, renouvellement), de la myéline ou d 'une inflammation (bétaïne)

Cr/PCr (Créatine-Phosphocréatine) : marqueur de densité cellulaire

Lac (Lactate) : témoin d 'un processus ischémique, d 'un dysfonctionnement mitochondrial ou d 'une infiltration macrophagique

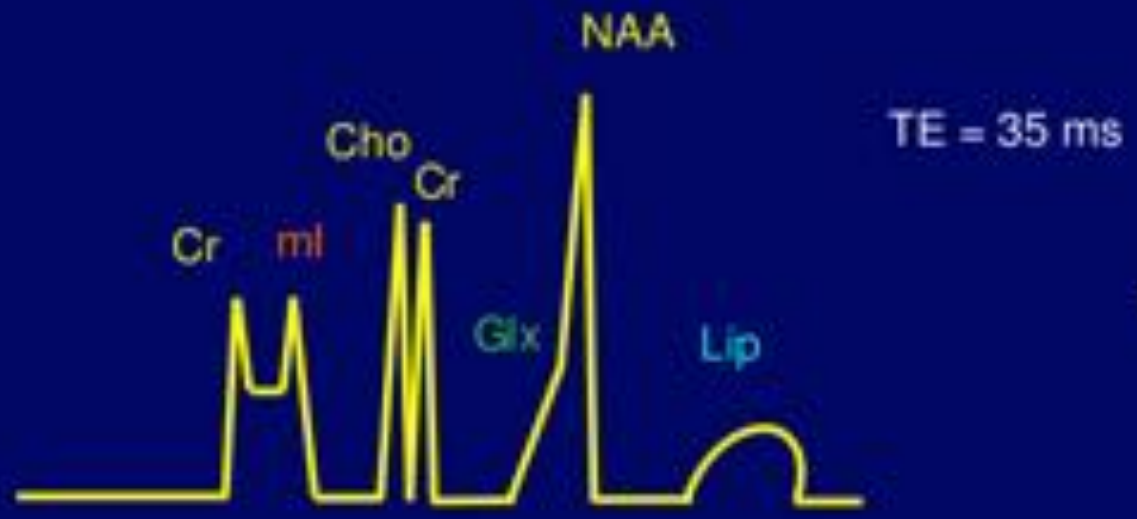

mI: myoinositol, glie normale

Glx: glutamine-glutamate, « neurotransmetteurs »

Lip: lipides, nécrose ou contamination (scalp)

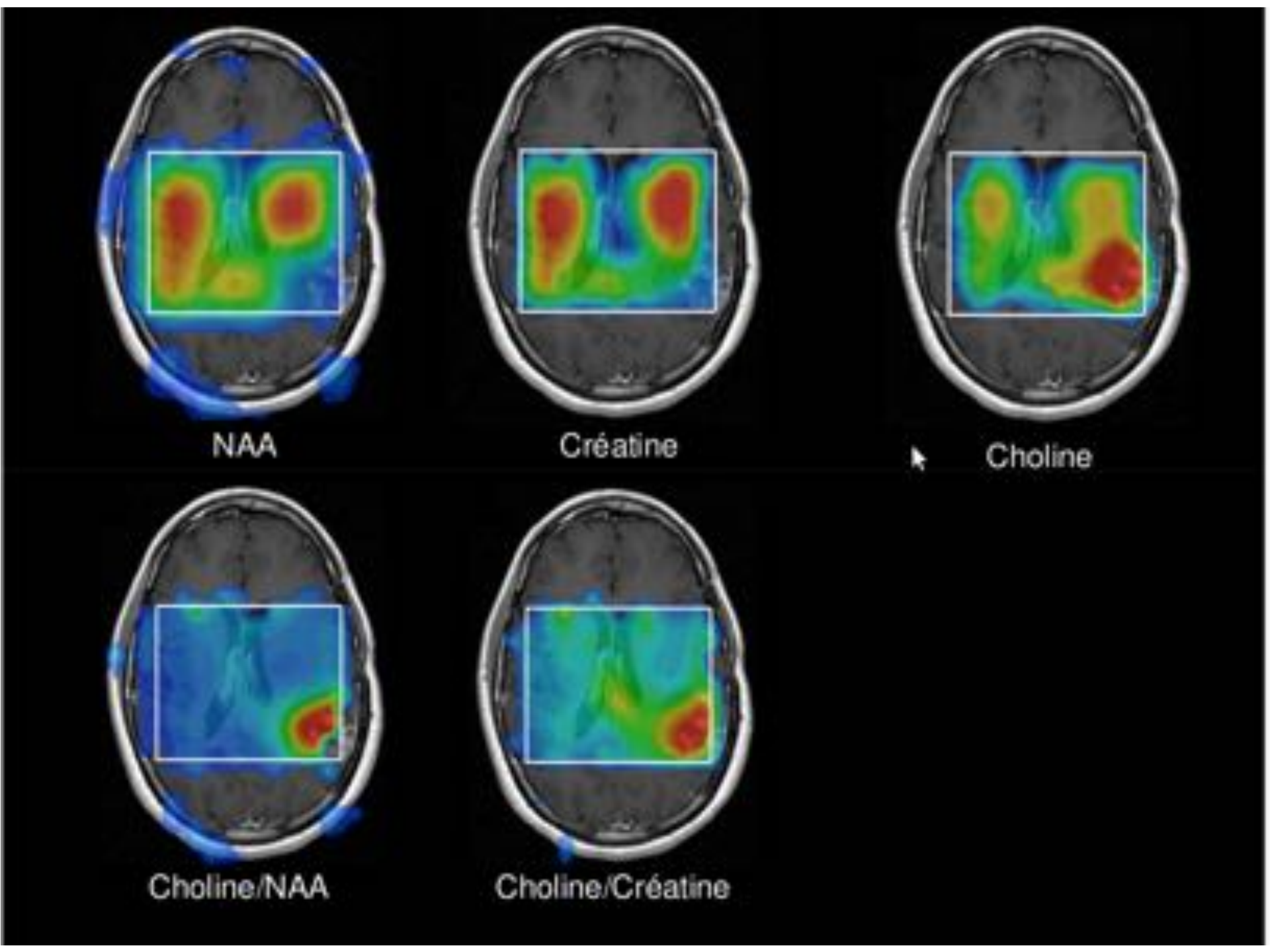
NAA
Créatine
Choline
Choline/NAA
Choline/Créatine

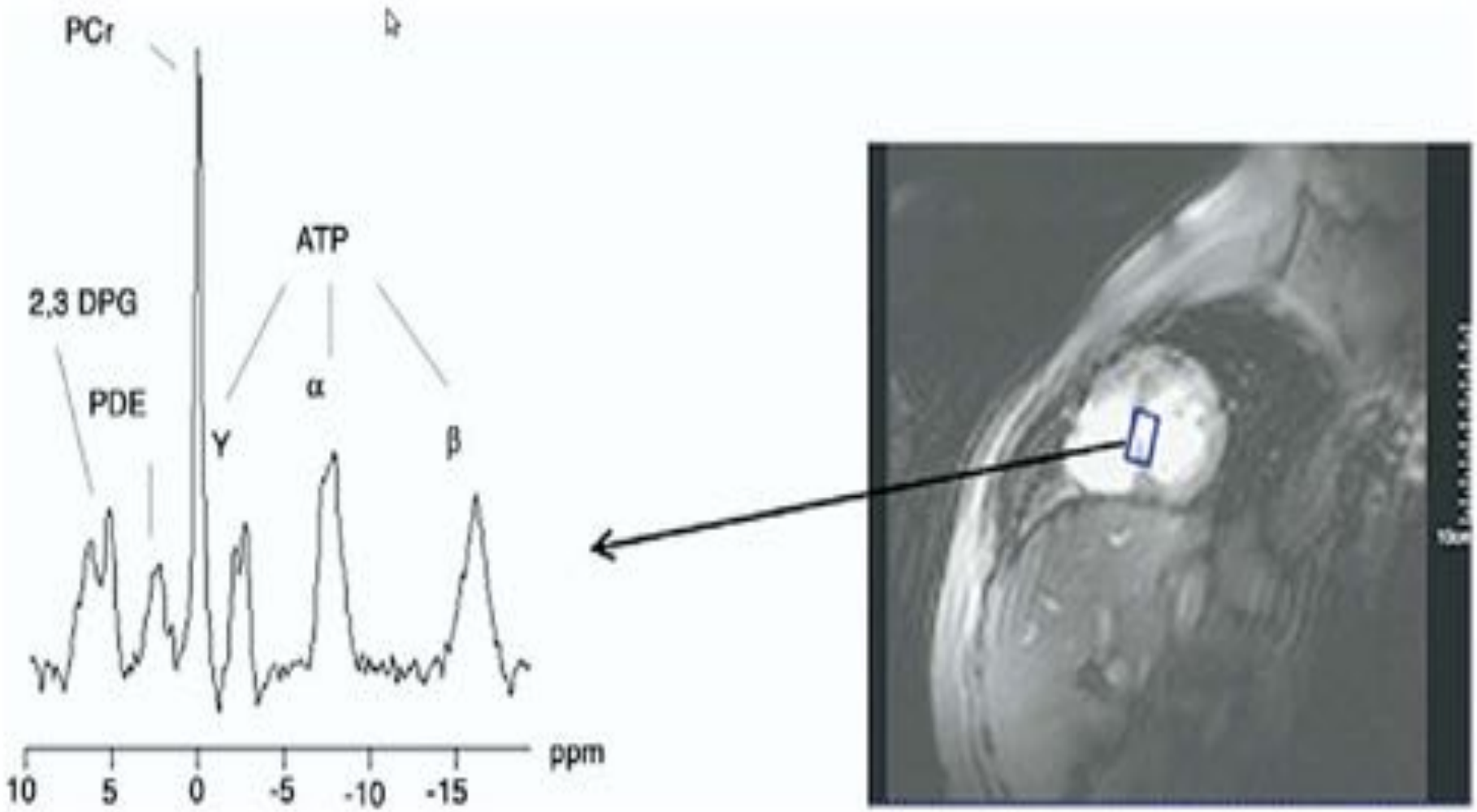

^{31}P Magnetic Resonance Spectroscopy in a Healthy Volunteer